

Progenitor-Enriched Adipose Tissue Transplantation as Rescue for Breast Implant Complications

Kotaro Yoshimura, MD,* Yuko Asano, MD,[†] Noriyuki Aoi, MD,* Masakazu Kurita, MD,[‡] Yoshio Oshima, MD,[†] Katsujiro Sato, MD,[†] Keita Inoue, MD,* Hirotaka Suga, MD,* Hitomi Eto, MD,* Harunosuke Kato, MD,* and Kiyonori Harii, MD[‡]

*Department of Plastic Surgery, University of Tokyo School of Medicine, Bunkyo-ku, Tokyo, Japan; [†]Cellport Clinic Yokohama, Minami-nakadori, Yokohama, Kanagawa, Japan; and [‡]Department of Plastic Surgery, Kyorin University School of Medicine, Mitaka-shi, Tokyo, Japan

■ **Abstract:** Breast enhancement with artificial implants is one of the most frequently performed cosmetic surgeries but is associated with various complications, such as capsular contracture, that lead to implant removal or replacement at a relatively high rate. For replacement, we used transplantation of progenitor-supplemented adipose tissue (cell-assisted lipotransfer; CAL) in 15 patients. The stromal vascular fraction containing adipose tissue progenitor cells obtained from liposuction aspirates was used to enrich for progenitor cells in the graft. Overall, clinical results were very satisfactory, and no major abnormalities were seen on magnetic resonance imaging or mammogram after 12 months. Postoperative atrophy of injected fat was minimal and did not change substantially after 2 months. Surviving fat volume at 12 months was 155 ± 50 mL (*Right*; mean \pm SD) and 143 ± 80 mL (*Left*) following lipoinjection from an initial mean of 264 mL. These preliminary results suggest that CAL is a suitable methodology for the replacement of breast implants. ■

Key Words: adipose-derived stem cells, autologous fat transplantation, breast prosthesis, cell therapy, complications

Implantation of artificial prostheses is a standard method of breast augmentation and is the most frequently performed cosmetic surgical procedure in US (approximately 347,000 cases in 2007) (1). However, complications derived from the foreign body, such as capsular contracture, malposition, implant rupture, and infection, occur at a relatively high rate (10–20%) (2–5) and frequently result in implant removal (approximately 27,000 cases in 2007) (1) or replacement of breast implants. While it is unlikely that the implant itself induces malignant changes, the presence of the implant could affect the rate of malignancy by reducing breast tissue visualization in the mammogram (6). Furthermore, there is potential for rupture when pressure is exerted on the implant during mammography, and for this reason, hospitals in Japan

reject women who have breast implants to undergo mammography as a part of annual social health examinations.

The use of autologous fat tissue as an alternative implant material for breast augmentation has not gained acceptance because of a lack of consensus on its safety and concern that the development of microcalcifications within the transplanted tissue could complicate mammogram evaluation (7). However, autologous fat tissue was recently re-evaluated as an alternative to artificial implants for breast augmentation or reconstruction (7–10), possibly reflecting recent technical advances in autologous fat transfer and the radiological detection of breast cancer. Although autologous fat transplantation offers many advantages, such as the lack of scarring and complications associated with foreign materials, the unpredictability and a low rate of graft survival because of partial necrosis are issues that remain to be resolved.

To address these problems, we developed a novel strategy called cell-assisted lipotransfer (CAL; Fig. 1). CAL was designed based on the finding that aspirated fat tissue contains many fewer vessels and adipose

Address correspondence and reprint requests to: Kotaro Yoshimura, MD, Department of Plastic Surgery, University of Tokyo School of Medicine, 7-3-1, Hongo, Bunkyo-Ku, Tokyo 113-8655, Japan, or e-mail: yoshimura-pla@h.u-tokyo.ac.jp.

DOI: 10.1111/j.1524-4741.2009.00873.x

© 2009 Wiley Periodicals, Inc., 1075-122X/09
The Breast Journal, Volume 16 Number 2, 2010 169–175

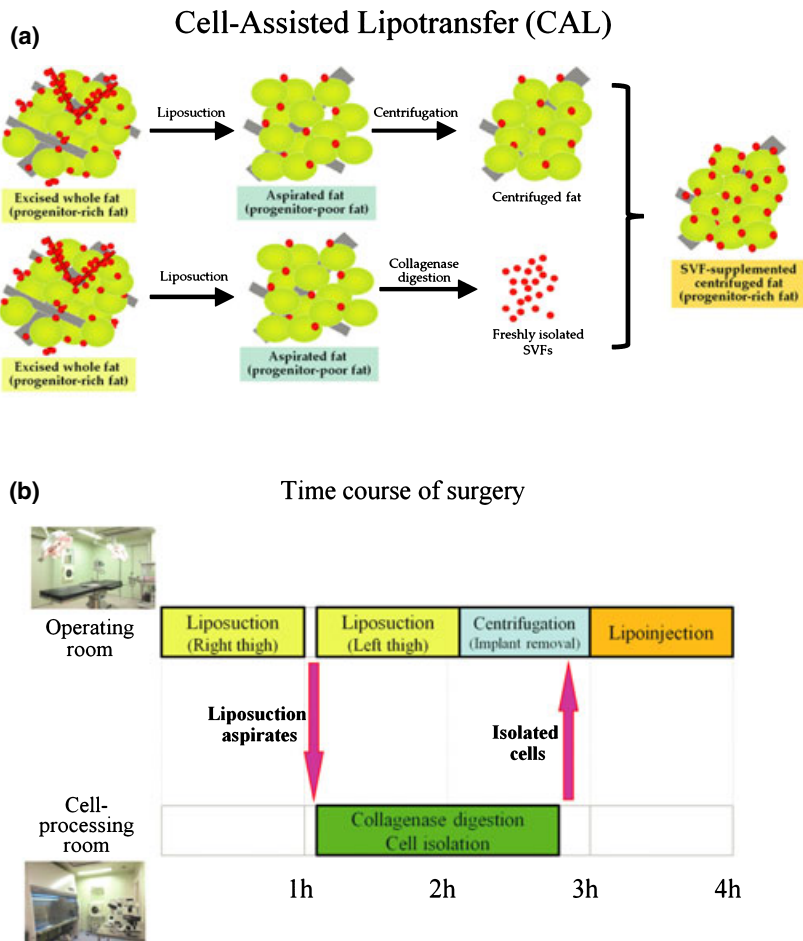


Figure 1. Procedure schemes. (a) Concept of cell-assisted lipotransfer (CAL). Relatively progenitor-poor aspirated fat tissue is converted to progenitor-rich fat tissue by supplementation with the stromal vascular fraction (SVF) isolated from one-half of the aspirated fat sample. SVF cells are attached to the aspirated fat tissue, which acts a scaffold in this strategy. (b) Time course for CAL breast replacement surgery. The operation begins with the harvesting of fat tissue for the isolation of SVF cells. While the cell isolation process is performed in a cell-processing room, implant removal and liposuction for graft material are performed in the operating room. After adding isolated the SVF to the centrifuged fat tissue, the mixture is injected into the breast. The entire procedure takes approximately 4 hours to complete.

progenitor cells than does intact fat tissue (11) and on our hypothesis that the ratio of progenitor cells to adult cells (adipocytes) is a critical factor for adipose tissue turnover as well as preservation of the surviving adipose tissue volume. The deficiency of progenitors in aspirated fat tissue may explain the progressive atrophy of transplanted aspirated fat tissue that occurs during the first 6 months of post-transplantation (11). In a clinical trial of CAL, the stromal vascular fraction (SVF) comprising 10–40% adipose progenitor cells (12,13) was freshly isolated from aspirated fat tissue via collagenase digestion and added to graft materials, converting relatively progenitor-poor fat tissue into progenitor-rich tissue.

MATERIALS AND METHODS

In this preliminary report, we analyzed the outcomes of 15 female patients who underwent CAL for immediate breast augmentation after breast implant removal. Patients participating in the trial did so

under informed consent approved by the individual review board. The concept and time course of the CAL procedure are shown in Figs. 1 and 2.

Surgical Techniques

The liposuction site was infiltrated with saline solution containing diluted epinephrine (0.0001%) while the patient was under general anesthesia, and then adipose tissue was suctioned using a 2.5-mm (inner diameter) cannula and a conventional liposuction machine. About half of the lipoaspirate was used for SVF isolation. The SVF was isolated from both the adipose and fluid portions of the liposuction aspirate as described previously (12); the cell processing procedure took about 90 minutes. The cell composition of the SVF was described previously (12,13). During processing, the other half of the lipoaspirate was harvested as graft material. Breast implants were removed through a periareolar incision, which was placed at the caudal third of the areola margin.

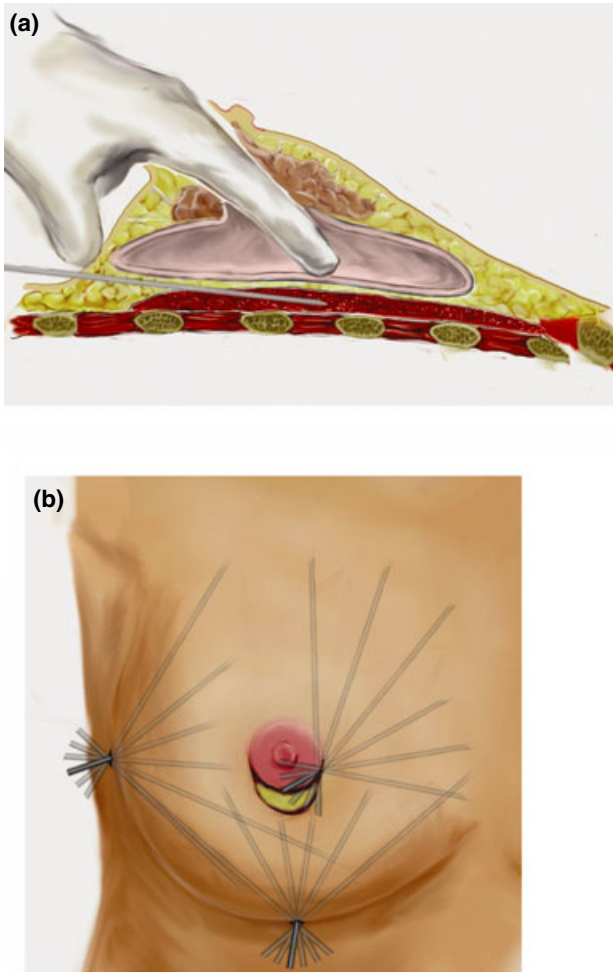


Figure 2. Schematic illustration of the injection method. (a) Using a long needle attached to a syringe with a threaded plunger, progenitor-supplemented fat tissue is injected while the needle is continuously withdrawn. The fat tissue is injected as a small aliquot or a thin string into layers other than the mammary gland and capsular cavity. While injecting, the fingers are inserted through a periareolar skin incision into the implant capsule to determine the location of the needle tip. Details of the surgical procedure are described below. (b) The needle is inserted either through a periareolar incision or at one of two points in the infra-mammary fold. The needle is aimed in various directions and into different planes to achieve a diffuse distribution.

The second half of the lipoaspirate was centrifuged at 700 g for 3 minutes without washing. After centrifugation, the oil and fluid portions were discarded, while the adipose portion was collected in a covered metal jar (500 mL) and placed in an ice water bath. The freshly isolated SVF was added to the centrifuged fat tissue and, after gentle mixing and a 10- to 15-minute incubation to achieve cell adhesion to the centrifuged fat tissue, the cell-supplemented fat tissue was placed into the injection syringe. The injection syringe

was a 10-cc LeVein™ inflator (Boston Scientific Corp., Natick, MA) or our original syringe (20 mL), which were used because both are screw-type syringes with threaded plungers and have threaded connections that fit both the connecting tube and the needle, allowing for precise control during the injection. Two syringes were used to minimize procedure time; while one syringe was being used for an injection, the other was filled with the graft material in preparation for the next injection. A 16- or 18-gauge sharp needle (150-mm long) was used for lipoinjection. The needle was inserted into several different layers and in different directions, and was continuously and gradually retracted as the plunger was advanced. Lipoinjection was initiated at the deepest layer under the implant capsule and completed with injection into the most superficial subcutaneous layer.

In the deepest layer, the operator took care to insert and maintain the needle horizontally (parallel to the body) to avoid damaging the pleura and causing a pneumothorax. The operator inserted a finger into the implant capsule, placed it on the bottom of the capsule, and determined the location of the injection needle.

When the original implants had been inserted under the pectoralis muscle, we often found the implant capsule adhered to the ribs. In these cases, the needle was inserted from the lateral margin of the breast and the needle tip was slid medially along a rib with great care. After injections along the ribs, the capsule was detached from the ribs and fat graft injection into the space under the capsule continued; injections were also made from a point on the inflammary fold. Lipoinjection between the capsule and the skin were performed from the same two points and from the periareolar incision. This technique was used to obtain a diffuse distribution of the graft material; injection into the mammary glands or the capsular cavity was not performed. Finally, the capsular cavity was washed with saline and the periareolar incision was closed. After the surgery, the breasts were held in position with a brassier and massage of the breasts was prohibited for 3 months.

Pre- and postoperative evaluations included mammography, magnetic resonance imaging (MRI), photography, videography, and three-dimensional (3D) measurements (Sppd-3E, Kiisya Ltd., Tokyo, Japan) that enabled volumetric evaluation of the breast mound with the patient in a standing position (Fig. 3).

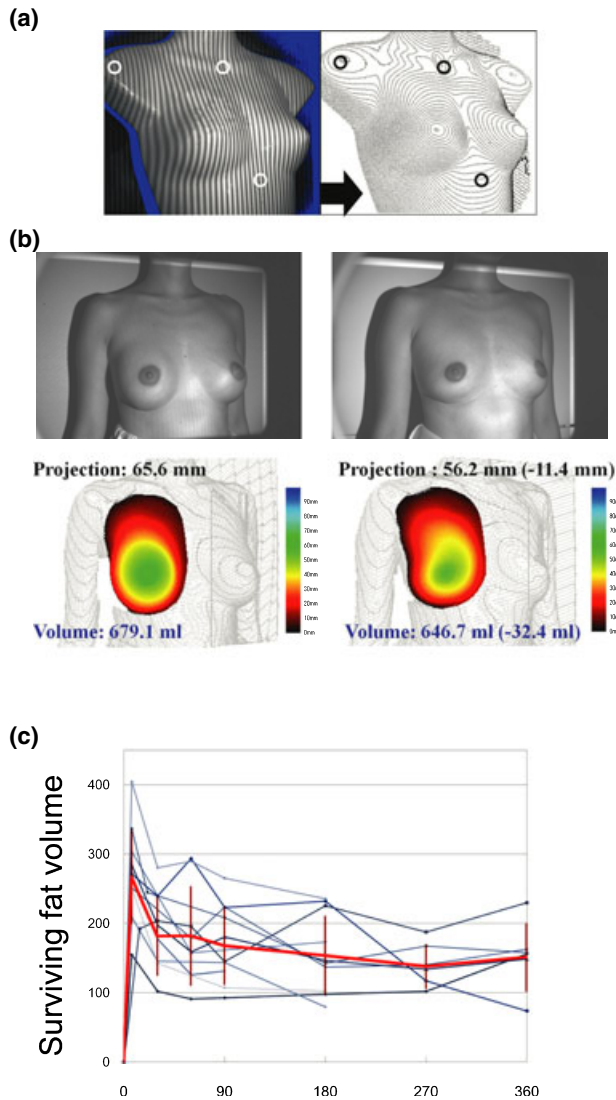


Figure 3. The three-dimensional measurement system. (a) Perpendicular striped lights are projected onto the body while the patient is in a standing position (left panel). Three points that do not usually shift after breast augmentation (shoulder, suprasternal notch, and xiphoid process) are plotted to designate a standard plane. Photos are taken using a stereo-type digital camera. Custom-made software (Kiisya Ltd., Tokyo, Japan) calculates the projection of the skin surface and draws contour lines (right panel). Then, the breast mound volume is calculated and recorded, along with the highest projection of the mound. (b) Representative data using the three-dimensional measurement system before (left panel) and 6 months after the surgery (right panel). Case 3 (see also Fig. 6) had 220-mL silicone gel implants before CAL. At 6 months after CAL, the breast projection and breast volume decreased by 11.4 mm and 32.4 mL, respectively, but the breast contour became more natural. (c) Sequential changes in the surviving fat volume. The red line shows the average and SD of data collected at each time point (as listed in Table 1), while other lines reflect individual data ($n = 10$). Surviving fat volume was calculated as $(\text{postoperative breast volume}) - (\text{preoperative breast volume}) + (\text{removed implant volume})$.

RESULTS

Cell-assisted lipotransfer was successful in all cases; 8 of the 15 patients were followed for more than 12 months (at the time of this report) and the maximum follow-up period was 18 months. Patient data and data regarding removed implants and postoperative breast measurements are summarized in Table 1. The 3D measurements showed that the transplanted adipose tissue was gradually absorbed during the first two postoperative months but that the breast volume showed changed minimally thereafter. The surviving fat volume was 155 ± 50 mL (Right; mean \pm SD) and 143 ± 80 mL (Left) at 12 months ($n = 6$: removed implant volume was not available for two patients;

Table 1. Summary of Patient Data

Number of cases	15	
Gender (f/m)	15/0	
Age (years)	37.1 ± 12.5	
BMI	19.5 ± 1.4	
	Right ($n = 15$)	Left ($n = 15$)
Removed implants (ruptured)		
Saline ($n = 4$)	2 (0)	2 (0)
Silicon ($n = 22$)	11 (5)	11 (4)
Hydrogel ($n = 4$)	2 (1)	2 (1)
Size of removed implants (mL) (N/A for six ruptured implants)	Right ($n = 12$) 201 ± 53	Left ($n = 12$) 196 ± 46
Site of liposuction	Thighs, 5 Thighs and abdomen, 10	
Volume of injection (mL)	Right ($n = 15$) 268 ± 29	Left ($n = 15$) 259 ± 39
Surviving fat volume (= changes in breast volume + removed implant size) (mL)	Right	Left
1 week ($n = 10$)	274 ± 68	264 ± 77
1 month ($n = 8$)	186 ± 57	206 ± 66
2 months ($n = 8$)	187 ± 72	190 ± 55
3 months ($n = 10$)	172 ± 57	182 ± 66
6 months ($n = 10$)	157 ± 58	150 ± 52
9 months ($n = 6$)	143 ± 32	160 ± 68
12 months ($n = 6$)	155 ± 50	143 ± 80
Changes in breast projection (mm)	Right	Left
1 week ($n = 10$)	-1.5 ± 6.1	1.4 ± 6.1
1 month ($n = 8$)	-3.5 ± 7.5	-3.6 ± 5.5
2 months ($n = 8$)	-5.3 ± 4.6	-4.2 ± 5.4
3 months ($n = 10$)	-4.5 ± 5.2	-6.3 ± 6.0
6 months ($n = 10$)	-8.3 ± 3.7	-6.5 ± 5.0
9 months ($n = 6$)	-10.5 ± 4.8	-6.2 ± 7.3
12 months ($n = 6$)	-9.2 ± 5.4	-7.9 ± 7.6

Removed implants are listed according to the type of substance they contained. Eleven of 30 implants were found to be ruptured at the time of removal and implant size was unrecognizable in six of these implants. Three-dimensional measurement of the breasts was accepted by and performed for 13 of 15 patients. Because of the unknown volume of ruptured implants, surviving fat volume was not calculated for 3 of the 13 patients; 12-month data were obtained for six of eight patients who were followed for more than 12 months because of unavailability of implant volume.

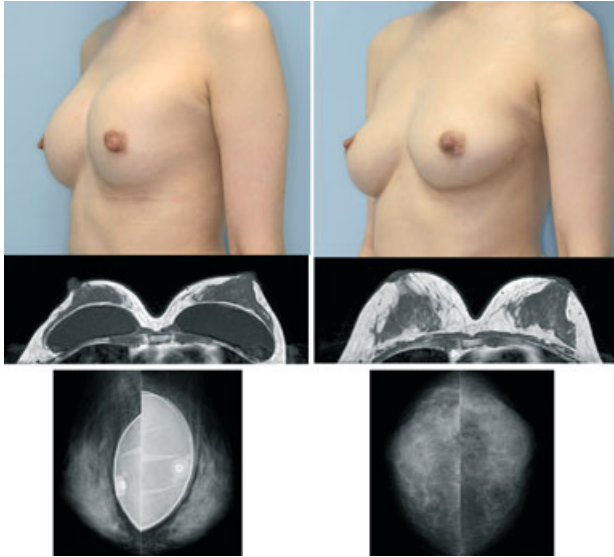


Figure 4. Clinical and radiological views of Case 1. Preoperative (left panels) and postoperative (right panels) views at 12 months. Clinical views showed capsular contracture and upward displacement of the left implant before surgery (top, left), while the breasts had a natural and symmetrical appearance at 12 months (top, right). T1-weighted MRI (middle, left, and right) revealed that the transplanted adipose tissue survived and formed thick layers around and under the mammary gland at 12 months. Mammograms showed that neither implant was ruptured before surgery (bottom, left) and that no calcification or other abnormal signs were visible in either breast at 12 months (bottom, right). Augmented breast mounds maintained sufficient breast volume even after implant removal, and were naturally soft without any subcutaneous indurations (see also Video S1).

Table 1, Fig. 3b,c), meaning that the graft take ranged from approximately 40% to 80%. Breast projection decreased by 9.2 ± 5.4 mm (*Right*) and 7.9 ± 7.6 mm (*Left*) at 12 months when compared with before implant removal. All patients showed natural breast softness without any palpable nodules at 12 months and all patients were satisfied with the texture, softness, contour, and symmetry of their breasts, as well as the absence of foreign materials. Pre- and postoperative photographs of representative patients, as well as their MRIs and mammograms, are shown in Figs. 4–7; videos of the same patients are available as Supporting Information online Videos S1–S4. No serious side-effects have been observed in the 15 patients; no cyst formation (>5 mm) or micro-calcifications were detected at 12 months ($n = 8$) by MRI or mammography. MRI analyses showed that the fatty layers around the mammary glands were substantially thicker at 12 months ($n = 8$) when compared with baseline (Figs. 4–7).

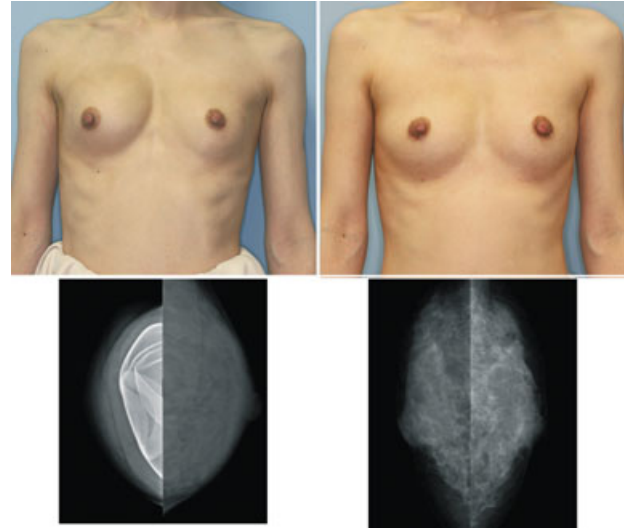


Figure 5. Clinical and radiological views of Case 2. Preoperative (left panel) and postoperative views at 12 months (right panel). Clinical views show capsular contractures and displacement of the right implant before surgery (top, left), while the breasts were symmetrical and had a natural appearance at 12 months (top, right). Mammograms showed that both implants were ruptured before surgery (bottom, left), and that no abnormal signs were present at 12 months (bottom, right). Augmented breast mounds were soft and natural-appearing without injection scars or subcutaneous indurations (see also Video S2).

DISCUSSION

Tissue-specific progenitor cells in adipose tissue can differentiate into various cell lineages (14,15). These progenitors, called “adipose-derived stem/stromal cells (ASCs),” are expected to become valuable tools in a wide range of cell-based therapies (15). ASCs are believed to act as progenitors of adipocytes and vascular cells (16), reside between adipocytes or in the extracellular matrix especially around vessels, and contribute to the turnover of adipose tissue (17), which is known to be very slow in humans (2–10 years) (17,18). The therapeutic concept of CAL was described in our previous pre-clinical (11) and clinical studies (9,19); we found that aspirated fat has approximately half the number of ASCs as excised whole fat tissue (11). We hypothesized that the relative deficiency of tissue-specific progenitors in aspirated fat tissue might contribute to the low survival rate and long-term atrophy of transplanted fat tissue, as was partially confirmed in animal studies (11,20,21). In the CAL strategy, the progenitor deficit was compensated for by supplementation with ASCs isolated from a separate volume of aspirated fat tissue. Speculated roles of ASCs in CAL are: (a) differentiate into adipocytes and contribute to adipose

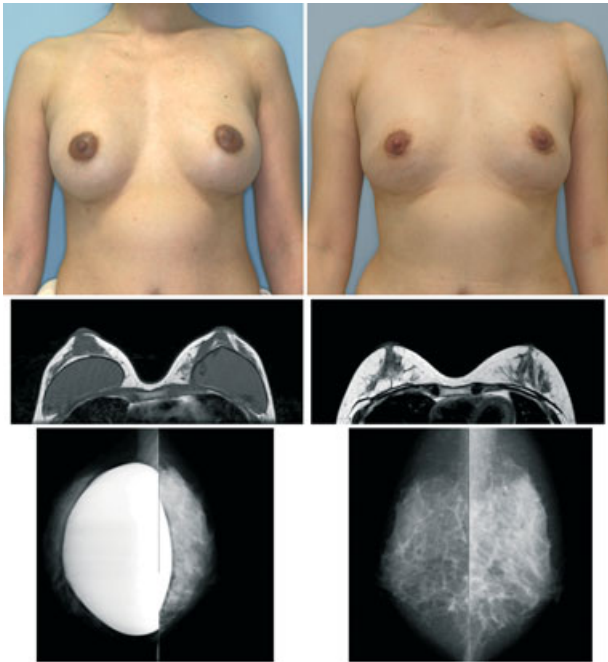


Figure 6. Clinical and radiological views of Case 3. Preoperative (left panel) and postoperative views at 12 months (right panel). Clinical views show capsular contracture resulting in an unnatural round shape of both breasts before surgery (top, left), while the breasts looked natural with a minimal loss of breast volume at 12 months (top, right). The T1-weighted MRI (middle, left, and right) revealed that the fatty layers around the mammary glands were thicker at 12 months when compared with baseline. Mammograms detected small calcifications in the right breast at 12 months (bottom, right), which were present before surgery and were not induced by lipoinjection (bottom, left). Augmented breast mounds were very soft and had natural skin texture with no visible injection scars (see also Video S3).

regeneration; (b) differentiate into vascular endothelial cells or mural cells and may promote angiogenesis (11,16,22); (c) release angiogenic growth factors such as hepatocyte growth factor (HGF) (22,23); and (d) survive as original ASCs (e.g., as adipose tissue progenitors) (11). Cellular and molecular events that occur in the grafted adipose tissue during the early phase (ischemia and subsequent reperfusion phase) after transplantation have not been well studied; however, adipose tissue and vessel remodeling occurs after experimental ischemia-reperfusion injury, and during the repair process, ASCs were a main proliferating cell population and promoted adipose tissue regeneration by releasing HGF (24).

Both the efficacy and safety of lipoinjection strongly depend on procedural techniques; lipoinjection is now performed for soft tissue augmentation of the face and other areas much more frequently than before because numerous technical innovations have rendered it

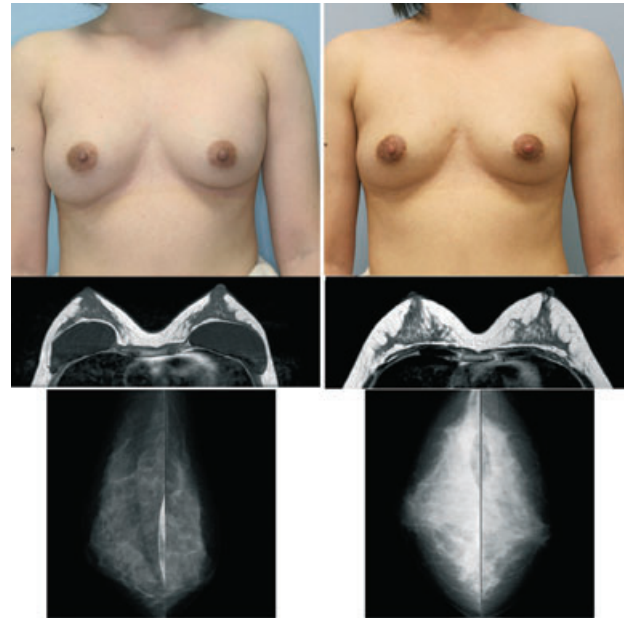


Figure 7. Clinical and radiological views of Case 4. Preoperative (left panel) and postoperative views at 12 months (right panel). Clinical views showed capsular contractures and downward displacement of the right implant before surgery (top, left), while the breasts were symmetrical and had a natural appearance at 12 months (top, right). The T1-weighted MRI (middle, left, and right) revealed that the fatty layers around the mammary glands were much thicker at 12 months than they were previously. Mammograms showed no calcifications or other abnormal signs in either breast before or at 12 months (bottom, left, and right). Augmented breast mounds maintained sufficient breast volume even after implant removal; they were naturally soft without any subcutaneous indurations or visible injection scars at 18 months (see also Video S4).

increasingly reliable (25–27). In this preliminary trial, no major complications were observed by MRI or mammography during 12 months of postoperative follow up, although ectopic fibrogenesis was previously reported when SVF cells were injected as a cell suspension separately from fat grafts (28). A substantial amount of the transplanted adipose tissue survived and was very well preserved for at least 12 months; breast implants were successfully replaced with the patients' own tissue with minimal volume loss. Thus, CAL can potentially be applied for the reconstruction or augmentation of any soft tissue defect. The surviving fat volume did vary substantially among patients, and the reasons for variations in volume enhancement among patients remain to be elucidated. Multiple factors are likely to affect the clinical results; patient factors include skin redundancy of the breast and technical factors include devices, graft fat preparation, and injection techniques (9,19,29).

In conclusion, given the high demand for breast enhancement and the high rate of complications derived from breast implants, replacing artificial implants with autologous tissue is a reasonable option, and CAL provides a feasible methodology. Further controlled studies with longer follow-up are required to elucidate more definitively the efficacy and safety of this procedure.

REFERENCES

1. American Society for Plastic Surgery. *National plastic surgery statistics 2007*. Available at: <http://www.plasticsurgery.org/media/statistics/loader.cfm?url=/commonspot/security/getfile.cfm&PageID=29287>.
2. Gabriel SE, Woods JE, O'Fallon WM, *et al*. Complications leading to surgery after breast implantation. *N Engl J Med* 1997;336:677–82.
3. Marotta JS, Widenhouse CW, Habal MB, Goldberg EP. Silicone gel breast implant failure and frequency of additional surgeries: analysis of 35 studies reporting examination of more than 8,000 explants. *J Biomed Mater Res* 1999;48:354–64.
4. Brown SL, Pennello G. Replacement surgery and silicone gel breast implant rupture: self-report by women after mammoplasty. *J Womens Health Gend Based Med* 2002;11:255–64.
5. Kjølner K, Hölmich LR, Jacobsen PH, *et al*. Epidemiological investigation of local complications after cosmetic breast implant surgery in Denmark. *Ann Plast Surg* 2002;48:229–37.
6. Tuli R, Flynn RA, Brill KL, *et al*. Diagnosis, treatment, and management of breast cancer in previously augmented women. *Breast J* 2006;12:343–8.
7. Coleman SR, Saboeiro AP. Fat grafting to the breast revisited: safety and efficacy. *Plast Reconstr Surg* 2007;119:775–85.
8. Spear SL, Wilson HB, Lockwood MD. Fat injection to correct contour deformities in the reconstructed breast. *Plast Reconstr Surg* 2005;116:1300–5.
9. Yoshimura K, Sato K, Aoi N, *et al*. Cell-assisted lipotransfer (CAL) for cosmetic breast augmentation – supportive use of adipose-derived stem/stromal cells. *Aesthetic Plast Surg* 2008;32:48–55.
10. Amar O, Bruant-Rodier C, Lehmann S, *et al*. Fat tissue transplant: restoration of the mammary volume after conservative treatment of breast cancers, clinical and radiological considerations. *Ann Chir Plast Esthet* 2008;53:169–77.
11. Matsumoto D, Sato K, Gonda K, *et al*. Cell-assisted lipotransfer: supportive use of human adipose-derived cells for soft tissue augmentation with lipoinjection. *Tissue Eng* 2006;12:3375–82.
12. Yoshimura K, Shigeura T, Matsumoto D, *et al*. Characterization of freshly isolated and cultured cells derived from the fatty and fluid portions of liposuction aspirates. *J Cell Physiol* 2006;208:64–76.
13. Suga H, Matsumoto D, Inoue K, *et al*. Numerical measurement of viable and non-viable adipocytes and other cellular components in aspirated fat tissue. *Plast Reconstr Surg* 2008;122:103–14.
14. Zuk PA, Zhu M, Ashjian P, *et al*. Human adipose tissue is a source of multipotent stem cells. *Mol Biol Cell* 2002;13:4279–95.
15. Gimble JM, Katz AJ, Bunnell BA. Adipose-derived stem cells for regenerative medicine. *Circ Res* 2007;100:1249–60.
16. Planat-Benard V, Silvestre JS, Cousin B, *et al*. Plasticity of human adipose lineage cells toward endothelial cells: physiological and therapeutic perspectives. *Circulation* 2004;109:656–63.
17. Spalding KL, Arner E, Westermarck PO, *et al*. Dynamics of fat cell turnover in humans. *Nature* 2008;453:783–7.
18. Strawford A, Antelo F, Christiansen M, Hellerstein MK. Adipose tissue triglyceride turnover, de novo lipogenesis, and cell proliferation in humans measured with $^2\text{H}_2\text{O}$. *Am J Physiol Endocrinol Metab* 2004;286:E577–88.
19. Yoshimura K, Sato K, Aoi N, *et al*. Cell-assisted lipotransfer for facial lipoatrophy: efficacy of clinical use of adipose-derived stem cells. *Dermatol Surg* 2008;34:1178–85.
20. Masuda T, Furue M, Matsuda T. Novel strategy for soft tissue augmentation based on transplantation of fragmented omentum and preadipocytes. *Tissue Eng* 2004;10:1672–83.
21. Moseley TA, Zhu M, Hedrick MH. Adipose-derived stem and progenitor cells as fillers in plastic and reconstructive surgery. *Plast Reconstr Surg* 2006;118(Suppl 3):121S–8S.
22. Miranville A, Heeschen C, Sengenès C, *et al*. Improvement of postnatal neovascularization by human adipose tissue-derived stem cells. *Circulation* 2004;110:349–55.
23. Rehman J, Traktuev D, Li J, *et al*. Secretion of angiogenic and antiapoptotic factors by human adipose stromal cells. *Circulation* 2004;109:1292–8.
24. Suga H, Eto H, Shigeura T, *et al*. FGF-2-induced HGF secretion by adipose-derived stromal cells inhibits post-injury fibrogenesis through a JNK-dependent mechanism. *Stem cells* 2009;27:238–49.
25. Coleman SR. Structural fat grafts: the ideal filler? *Clin Plast Surg* 2001;28:111–9.
26. Ersek RA, Chang P, Salisbury MA. Lipo layering of autologous fat: an improved technique with promising results. *Plast Reconstr Surg* 1998;101:820–6.
27. Har-Shai Y, Lindenbaum ES, Gamliel-Lazarovich A, *et al*. An integrated approach for increasing the survival of autologous fat grafts in the treatment of contour defects. *Plast Reconstr Surg* 1999;104:945–54.
28. Yoshimura K, Aoi N, Suga H, *et al*. Ectopic fibrogenesis induced by transplantation of adipose-derived progenitor cell suspension immediately after lipoinjection. *Transplantation* 2008;85:1868–9.
29. Kurita M, Matsumoto D, Shigeura T, *et al*. Influences of centrifugation on cells and tissues in liposuction aspirates: optimized centrifugation for lipotransfer and cell isolation. *Plast Reconstr Surg* 2008;121:1033–41.

SUPPORTING INFORMATION

Additional Supporting Information may be found in the online version of this article:

Video S1. Case 1 before CAL and 12 months after CAL.

Video S2. Case 2 before CAL and 12 months after CAL.

Video S3. Case 3 before CAL and 12 months after CAL.

Video S4. Case 4 before CAL and 18 months after CAL.

Please note: Wiley-Blackwell are not responsible for the content or functionality of any supporting materials supplied by the authors. Any queries (other than missing material) should be directed to the corresponding author for the article.