

# Vertical Enlargement of the Palpebral Aperture by Static Shortening of the Anterior and Posterior Lamellae of the Lower Eyelid: A Cosmetic Option for Asian Eyelids

Toshitsugu Hirohi, M.D.  
Kotaro Yoshimura, M.D.

*Tokyo, Japan*

**Background:** Although double eyelid plasty, levator aponeurotic surgery, and epicanthoplasty are well-accepted cosmetic treatments for Asian eyes, some patients are incompletely satisfied with the outcomes and request further surgery. Although lower eyelid descent is generally recognized as a symptom of aging or a complication after blepharoplasty, the authors propose a perceptual change: a lowering the lower eyelid procedure to vertically enlarge the palpebral aperture in selected Asian patients.

**Methods:** A total of 125 Japanese patients underwent the lowering the lower eyelid procedure between 2005 and 2009. The main indications were patients with vertically narrow palpebral aperture or an up-slanting appearance. The lowering the lower eyelid procedure is performed by a combination of the removal of approximately 4 to 6 mm of the subciliary skin (usually the lateral one-third to two-thirds of the lower eyelids) and static shortening of the lower eyelid retractors (posterior lamella) through a transconjunctival approach. The middle lamella was not touched during the procedure.

**Results:** The up-slanting lower eyelid margin was lowered and the lateral part of the palpebral aperture was enlarged by the procedure in all cases. Cosmetic outcomes were encouraging and satisfying to most patients. Three complications occurred (2.4 percent): lagophthalmos in one patient (0.8 percent) and entropion in two patients (1.6 percent). These minor complications resolved within 1 month. Eight revision operations were required for undercorrection.

**Conclusions:** The lowering the lower eyelid procedure offers Asian patients desiring large oval eyes a novel surgical option. The procedure proved to be a reliable and consistent technique that provided satisfactory results in carefully selected patients. (*Plast. Reconstr. Surg.* 127: 396, 2011.)

A number of previous reports have focused on retraction of the lower eyelids, but always from negative points of view. Not only the aging process but also lower blepharoplasty can cause descent of the lower eyelid (occasionally along with medial migration of the lateral canthus), resulting in rounding of the palpebral aperture.<sup>1-3</sup> Because these unfavorable situations are generally can-

didates for surgical treatment, a considerable volume of the literature describes how to treat and how to avoid lower eyelid malposition such as inferior scleral show and cicatricial ectropion.<sup>4-9</sup>

Typical characteristics of the Asian eyelid include puffiness, single (nonfolded) upper eyelid, epicanthus, up-slanting appearance, vertically narrow palpebral aperture, and deep-set eyes (Fig. 1). These distinctive features sometimes project an impression of tiredness, maliciousness, or anger. Although a youthful palpebral aperture has been occasionally described as horizontally wide and

*From the Ritz Cosmetic Surgery Clinic Tokyo and the Department of Plastic Surgery, University of Tokyo School of Medicine.*

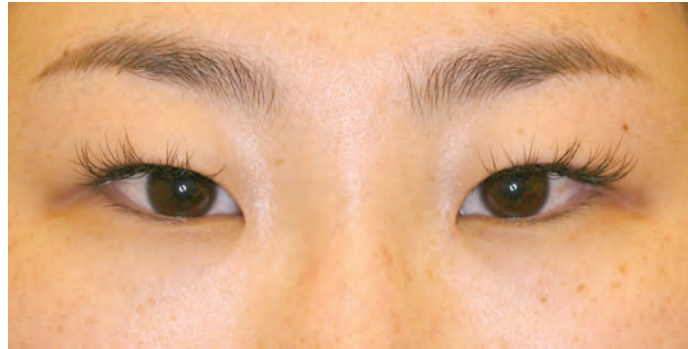*Received for publication March 15, 2010; accepted June 22, 2010.*

*Presented at the 32nd Meeting of the Japanese Society of Aesthetic Plastic Surgery, in Yokohama, Japan, on September 25, 2009.*

*Copyright ©2010 by the American Society of Plastic Surgeons*

DOI: 10.1097/PRS.0b013e3181f95b09

**Disclosure:** *The authors declare that they have no competing financial interests.*



**Fig. 1.** A representative view of the typical Asian eyelid in a 24-year-old Japanese woman: puffiness, single (nonfolded) eyelid, epicanthal fold, up-slanting lower eyelid margin, vertically narrow palpebral aperture, and deep-set eyes. The anatomical parameters of her eyes were measured. The height of the palpebral fissure at the midpupil point was 7.6 mm on the right and 7.7 mm on the left. The inclination between the medial canthus and lateral canthus was unexpectedly within normal limits (9.4 degrees on the right and 11.7 degrees on the left). Thus, anatomically positive palpebral tilt was not detected, although the eyes appeared up-slanting. The epicanthal fold and the up-slanting lower eyelid margin are suspected to be two predominant factors causing the up-slanted appearance.

vertically narrow in the West,<sup>1</sup> many Asian women consider that vertically larger (oval-shaped) eyes are more attractive. Therefore, procedures such as double-eyelid plasty, levator aponeurotic surgery, eye brow lifting, epicanthoplasty, and lateral canthoplasty are generally performed to satisfy Asian patients' desires. Although these operations are well accepted and certainly effective, we found that some patients were not fully satisfied with the postoperative results and requested additional surgery to achieve their ultimate expectations. Through analyses of the discontent of these patients, we developed a surgical solution by focusing on the position and shape of the lower eyelid margin. The up-slanting appearance of the palpebral aperture in Asians is frequently derived not from anatomically positive canthal tilt but from combined effects of the epicanthus and the up-slanting lateral half of the lower eyelid margin. To the best of our knowledge, no cosmetic procedure or concept has been presented for vertical enlargement of the palpebral aperture by lowering the lower eyelid; many known procedures seek to enlarge palpebral aperture by shifting the eyelid margin in the superior, medial, or lateral directions, but not in the inferior direction. We found that an inferior alteration of the lower eyelid is applicable to carefully selected Asian patients to satisfy their ultimate goals.

## PATIENTS AND METHODS

A total of 125 Japanese patients underwent the primary lowering the lower eyelid procedure between November of 2005 and July of 2009. The patients included 12 men and 113 women, with an average age of 26.6 years (range, 20 to 48 years). Of the 125 patients, four underwent the unilateral lowering the lower eyelid procedure to correct palpebral asymmetry. Fifty-nine patients underwent the lowering the lower eyelid procedure only, and the remaining 66 underwent it in combination with other procedures. The concomitant surgery included levator aponeurotic surgery in 23 patients, medial epicanthoplasty in 20 patients, double eyelid surgery in 14 patients, upper eyelid blepharoplasty in five patients, subbrow blepharoplasty for upper eyelid rejuvenation in two patients, and lower eyelid blepharoplasty in two patients (Table 1).

### Preoperative Evaluations

To avoid postoperative complications such as inferior scleral show or ectropion, careful preoperative evaluations are required. In particular, the lower eyelid tone and the protrusion of the eyeballs are two important factors to evaluate. The lower eyelid tone is evaluated as described previously.<sup>9-12</sup> In brief, the lower eyelid is

**Table 1. Concomitant Procedures Performed with the Lowering the Lower Eyelid Procedure**

	No. of Patients
Levator aponeurotic surgery	23
Medial epicanthoplasty	20
Double eyelid plasty	14
Upper lid blepharoplasty	5
Subbrow blepharoplasty	2
Lower lid blepharoplasty	2
None (LEE procedure alone)	59
Total	125

LEE, lowering the lower eyelid.

gently pulled down, away from the globe, and then allowed to retract back into its regular anatomical position. If the lower eyelid snaps back firmly, it indicates healthy tone and elasticity. Delayed or no recovery signifies a potential risk for postoperative malposition. In addition, the anterior projection of the eyeball and the malar eminence should be compared on the lateral view.<sup>10,13</sup> Patients whose malar eminence lies posterior to their cornea (so-called negative vector) could have poor lower eyelid support, which means a higher risk of postoperative malposition.<sup>14–16</sup>

### Preoperative Consultation and Informed Consent

Even a subtle change in shape and location of the lower eyelid can lead to a dramatic difference in appearance; thus, it is imperative that the patient is adequately informed to ensure satisfaction with the postoperative outcome. In the first consultation, patients were shown a variety of photographs obtained before and after the lowering the lower eyelid procedure in patients with a change ranging from slight to dramatic. Through this process, the patient can identify the degree of change that they desire. Such careful consultation is of

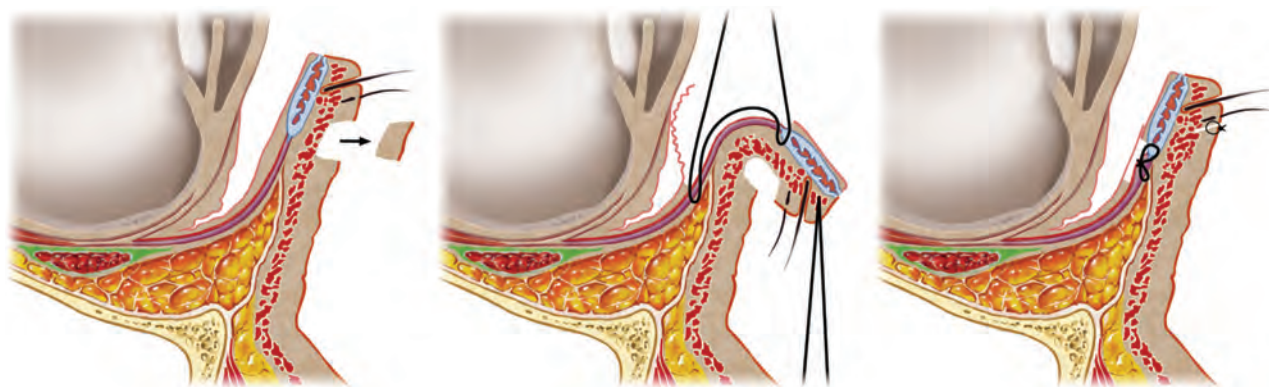
paramount importance to avoid a misunderstanding between the surgeon and patient.

### Operative Procedures

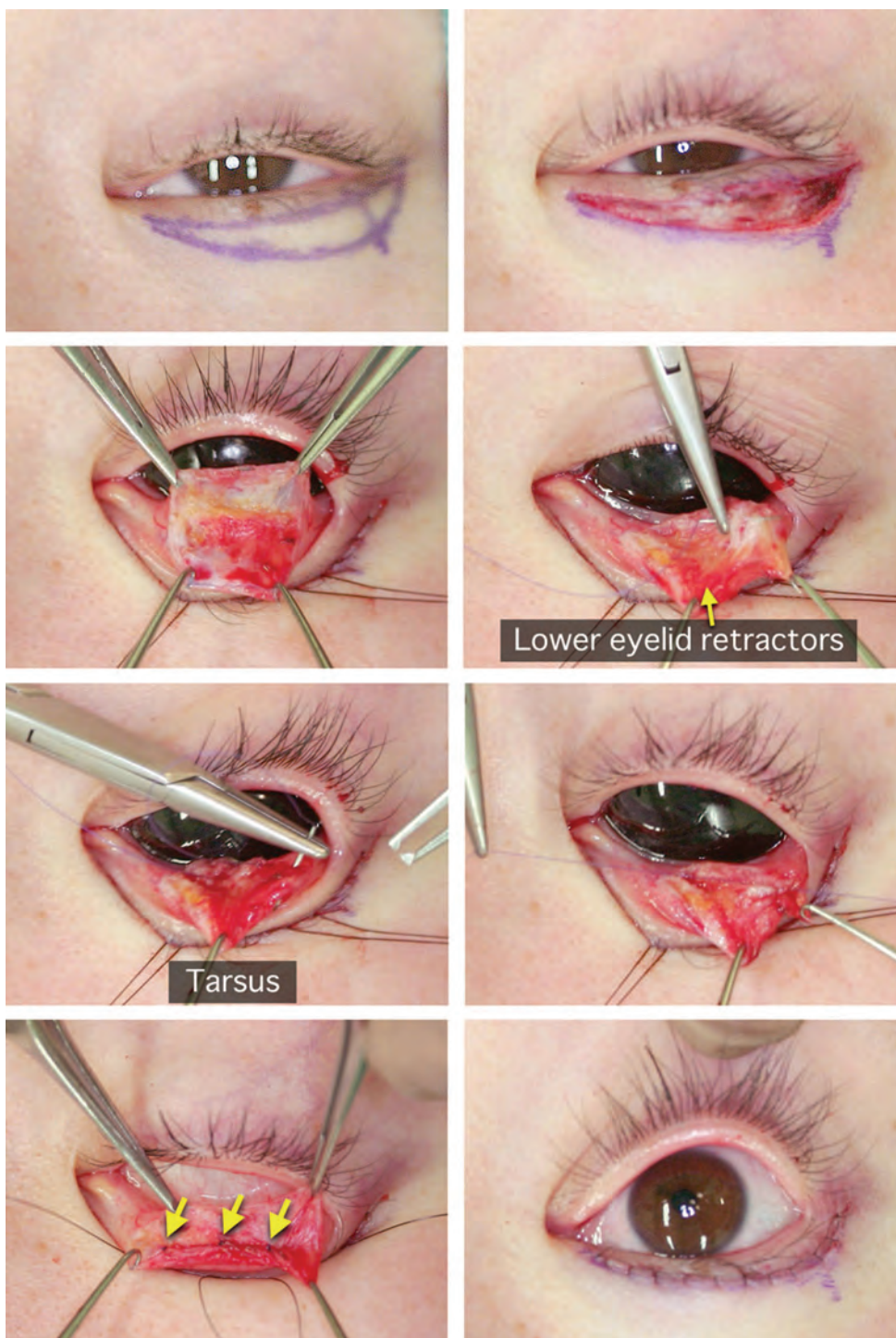
The lowering the lower eyelid procedure is routinely performed through both the transcutaneous and transconjunctival approaches under local anesthesia (1% lidocaine with 1:100,000 epinephrine). A step-by-step sagittal-section schema and anterior view photographs of the lowering the lower eyelid procedure are shown in Figures 2 and 3, respectively.

Preoperative designing of the skin excision was performed while the patient was in a sitting position with the eyes open and the lower eyelid skin under downward tension. A subciliary incision was made 2 mm inferior to the ciliary margin, and the skin excision was planned according to each patient's condition and preference; the excised skin was usually 4 to 6 mm in vertical maximum width at approximately half the distance between the lateral limbus of the cornea and lateral canthus (Fig. 3, *above, left*). The incision was made according to each patient's condition (e.g., medially from a point at approximately half the distance between the medial canthus and medial limbus of the cornea, and laterally to the lateral canthus) (Fig. 3, *above, right*). The skin incision was made with preservation of the orbicularis oculi muscle intact (Fig. 2, *left*). All bleeding vessels were meticulously cauterized with a bipolar cautery.

Next, a protective contact lens was applied to protect the cornea and eyeball, and the lower eyelid was then everted by pulling a traction suture placed at the eyelid margin (Fig. 3, *second row, left, second row, right, third row, left, third row, right, and below, left*). After a conjunctival incision was made



**Fig. 2.** Sagittal-section schema of the lowering the lower eyelid procedure. (*Left*) Subciliary skin (anterior lamella) is removed. (*Center*) Posterior lamella shortening is performed by suturing the lower eyelid retractors to the inferior edge of the tarsal plate. (*Right*) The lower eyelid margin is inferiorly repositioned by shortening the anterior and posterior lamella.

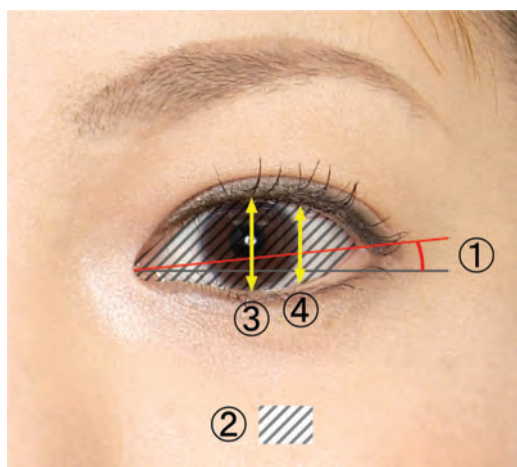


**Fig. 3.** Step-by-step anterior views of the lowering the lower eyelid procedure. (Above, left) Preoperative design for skin removal. (Above, right) The anterior lamella (eyelid skin) was removed. (Second row, left) The palpebral conjunctiva was incised and dissected inferiorly. (Second row, right) A 5-0 polydioxanone suture was passed through the lower eyelid retractor. (Third row, left) The polydioxanone suture was then passed through the inferior edge of the tarsus as well. (Third row, right) The posterior lamella was shortened by tying the suture. (Below, left) Three tucking stitches were placed. (Below, right) The subciliary skin defect was finally closed with 7-0 black nylon.

just below the inferior border of the tarsal plate, dissection was extended inferiorly by approximately 8 mm (Fig. 3, *second row, left*). The posterior lamella was shortened; the degree of shortening was usually decided as the excised margins of the anterior lamella were just overlapped. The lower eyelid retractor was sutured to the inferior edge of the tarsal plate with three stitches using 5-0 polydioxanone suture (Novartis Animal Health U.S., Inc., Greensboro, N.C.) (Fig. 2, *center* and Fig. 3, *second row, right, third row, left, third row, right, and below, left*). Lastly, the skin was closed with a 7-0 black nylon suture, and the surgeon made a final check with the patient in the sitting position (Figs. 2, *right* and 3, *below, right*). If asymmetry, overcorrection, undercorrection, or entropion was observed, it was corrected immediately by adjusting the posterior lamella shortening through the transconjunctival approach.

### Morphometric Measurements

Standardized photographs of frontal close-up views were obtained and used for measurements. The four anatomical parameters—inclination between medial canthus and lateral canthus, area of palpebral aperture, height of palpebral aperture at the midpupil, and height of palpebral aperture at the lateral limbus margin—were measured for clinical evaluation. An examiner obtained the measurements using Mirror software (Canfield Scientific, Inc., Fairfield, N.J.) (Fig. 4); double measurements were obtained and the mean value for each case was calculated.



**Fig. 4.** Measured parameters for preoperative and postoperative evaluations. 1, The inclination between the medial canthus and the lateral canthus; 2, the area of the palpebral aperture; 3, the height of the palpebral aperture at the midpupil point; and 4, the height of the palpebral aperture at the lateral limbus margin.

## RESULTS

The majority of patients were satisfied with the aesthetic outcomes. The palpebral aperture was vertically enlarged in all cases. The lateral scleral triangle became larger postoperatively, resulting in an S-shaped lower eyelid margin.

During follow-up ranging from 1 to 48 months (mean, 8 months), no major complications such as ectropion or scleral show were observed. Minor complications were seen in three patients (2.4 percent): lagophthalmos in one (0.8 percent) and entropion in two (1.6 percent) patients, and all of these resolved within 1 month without specific treatment. Lagophthalmos was seen in one of 23 patients who underwent levator aponeurotic surgery concomitantly. Entropion occurred because of an imbalance between anterior lamella removal and posterior lamella shortening.

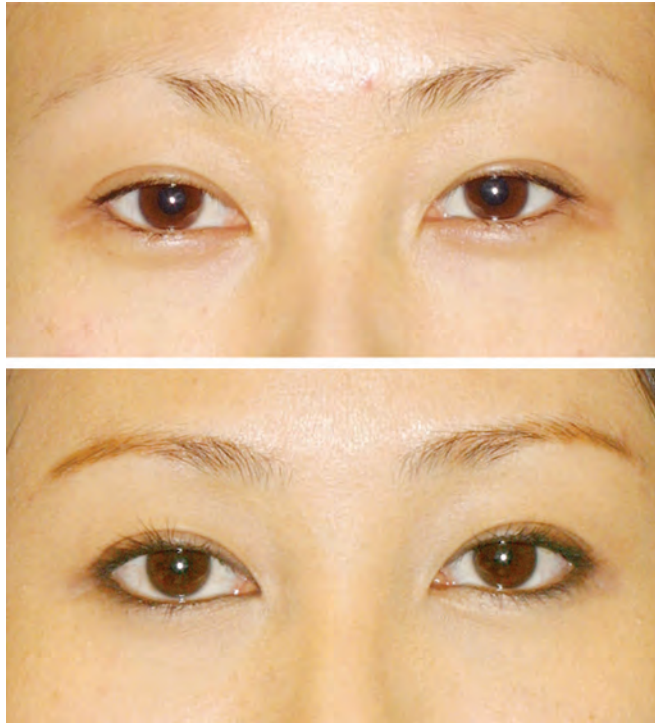
Conjunctival chemosis sometimes occurred postoperatively, but it subsided spontaneously within a couple of weeks in most cases. Only four patients (3.2 percent) suffered from prolonged chemosis; however, they recovered fully within 6 months with a treatment of eyedrops (preservative-free artificial tears); there was no need for a temporary suture tarsorrhaphy. Two patients complained of diplopia immediately after the operation, but both of them recovered within 1 day. A small minority of patients were not fully satisfied with the aesthetic results, including slight asymmetry and undercorrection. A revision operation (additional shortening by 2 to 4 mm) was performed in eight patients to treat undercorrection in response to patient request; all of the patients were early cases in the present series. A total of 8 mm (5 mm during the primary operation and 3 mm during the secondary operation) was the greatest amount of skin that was safely excised in revision cases.

## CASE REPORTS

Representative patients are shown in Figures 5 through 8. Preoperative and postoperative data are listed in Table 2.

## DISCUSSION

Lower eyelid malposition is the most common complication after lower eyelid blepharoplasty,<sup>17,18</sup> for which three major mechanisms are recognized. First, removing excessive anterior lamella causes the lower eyelid margin to descend. Second, and by far the most common cause of eyelid malposition, is a shortening of the middle lamella (orbital septum) caused by scarring or adhesion

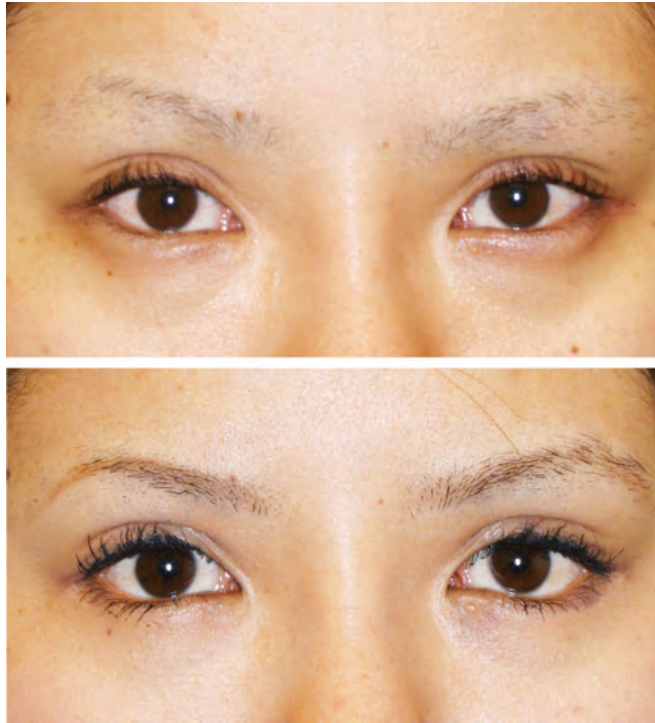

**Fig. 5.** Patient 1 (lowering the lower eyelid procedure only). A 24-year-old woman complained about the up-slanting appearance of her eyes (*above*), although the inclination between the medial canthus and the lateral canthus was within normal limits on both sides (right, 11.6 degrees; left, 11.2 degrees). Five millimeters of the lower eyelid skin was resected on both sides in the lowering the lower eyelid procedure, which made her lateral scleral triangle moderately larger, resulting in bright-appearing eyes (at 18 months; *below*). Morphometric evaluation showed that both the height of her palpebral aperture at the midpupil and the height of her palpebral aperture at the lateral limbus margin increased. The height of her palpebral aperture at the midpupil increased from 8.5 mm to 9.9 mm for the right eye and from 8.3 mm to 9.0 mm for the left eye. The height of palpebral aperture at the lateral limbus margin increased from 6.0 mm to 7.7 mm for the right eye and from 5.9 mm to 7.6 mm for the left eye.

with the capsulopalpebral fascia.<sup>4,19</sup> Third, posterior lamella deficiency (or excessive removal) usually presents as entropion.<sup>9</sup> In the lowering the lower eyelid procedure, ectropion or entropion was prevented by the static and balanced shortenings of the anterior and posterior lamellae. The middle lamella was shortened but never touched during the procedure, minimizing the risk of cicatricial or adhesional shortening of the middle lamella.

We consider that primary indications for the lowering the lower eyelid procedure are a vertically narrow palpebral aperture and an up-slanting appearance. The cornea is generally more concealed

by the lower eyelid in Asians than in Caucasians. In our opinion, a wider exposure of the cornea than in Caucasians would be aesthetically preferred by many Asians. To treat the vertically narrow palpebral aperture, a variety of upper eyelid blepharoplasty procedures, such as levator aponeurotic surgery, is primarily indicated, but some patients were not fully satisfied without further exposure of the lower part of the cornea, which required manipulation of the lower eyelid. The lowering the lower eyelid procedure can be performed as an ancillary procedure in cases with normal canthal tilt (inclination between medial canthus and lateral canthus, 10 to 15 degrees),<sup>20</sup> and combining it with levator

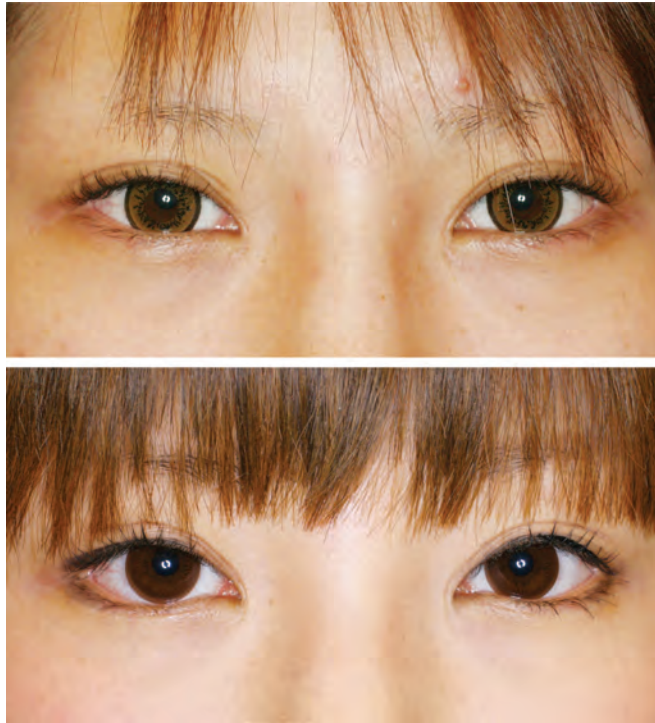

**Fig. 6.** Patient 2 (lowering the lower eyelid procedure only). The chief complaint of this 23-year-old woman was her hard-appearing eyes (*above*), although the inclination between her medial canthus and lateral canthus was within normal limits on both sides (right, 12.2 degrees; left, 13.6 degrees). The preoperative shape and position of her lower eyelids were asymmetric; the lower eyelid skin was resected in the lowering the lower eyelid procedure by widths of 5 and 7 mm on the right and left sides, respectively. Morphometry at 10 months showed that the height of her palpebral aperture at the midpupil increased from 8.9 mm to 9.7 mm on the right side and from 9.0 mm to 10.1 mm on the left side (*below*). The height of her palpebral aperture at the lateral limbus margin increased from 7.0 mm to 7.9 mm on the right side and from 7.4 mm to 8.3 mm on the left side. Furthermore, the area of palpebral aperture increased from 1.63 cm<sup>2</sup> to 1.76 cm<sup>2</sup> on the right side and from 1.57 cm<sup>2</sup> to 1.79 cm<sup>2</sup> on the left side. Although her left lower lid appeared slightly overcorrected postoperatively, the result met her expectations.

aponeurotic surgery would be the best strategy to vertically enlarge the palpebral aperture. Canthal tilt should be evaluated preoperatively, and lateral canthoplasty is recommended to lower the lateral canthal position in case of positive canthal tilt (inclination between medial canthus and lateral canthus  $\geq 15$  degrees).<sup>21,22</sup>

Some other noteworthy points during the preoperative assessments for the lowering the lower eyelid procedure include the horizontal laxity and vertical position of the lower eyelid, and the relative positions of the eyeball and malar promi-

nence. It was reported that the mean vertical height of the palpebral aperture was  $8.2 \pm 1.1$  mm in Asian women,<sup>23</sup> and the lower eyelid is normally positioned 1 to 2 mm above the inferior limbus.<sup>20</sup> Although the absolute height is not essential in preoperative evaluation, the distance between the corneoscleral junction and the lower eyelid margin must be noted. If the lowering the lower eyelid procedure is performed within the lateral third of the lower eyelids, the area of palpebral aperture can be enlarged without lowering the lower eyelid margin at the point of the inferior limbus. The



**Fig. 7.** Patient 3 (lowering the lower eyelid procedure only). A 19-year-old woman complained not only about her vertically narrow palpebral aperture but also felt that she had tough-appearing eyes, possibly caused by the up-slanting lateral lower eyelid (*above*). Note that she wore cosmetic tinted contact lenses with an opaque color to accentuate the iris rim. In the lowering the lower eyelid procedure, 5 and 6 mm of the lower eyelid skin was removed on the right and left sides, respectively. Her lateral scleral triangle became enlarged, leading to more bright-appearing eyes (at 10 months; *below*). Morphometric evaluation showed that the height of palpebral aperture at the midpupil and the height of palpebral aperture at the lateral limbus margin increased. The height of palpebral aperture at the midpupil increased from 8.2 mm to 9.3 mm on the right side and from 8.0 mm to 8.8 mm on the left side. The height of palpebral aperture at the lateral limbus margin increased from 6.4 mm to 8.0 mm on the right side and from 7.0 mm to 8.2 mm on the left side.

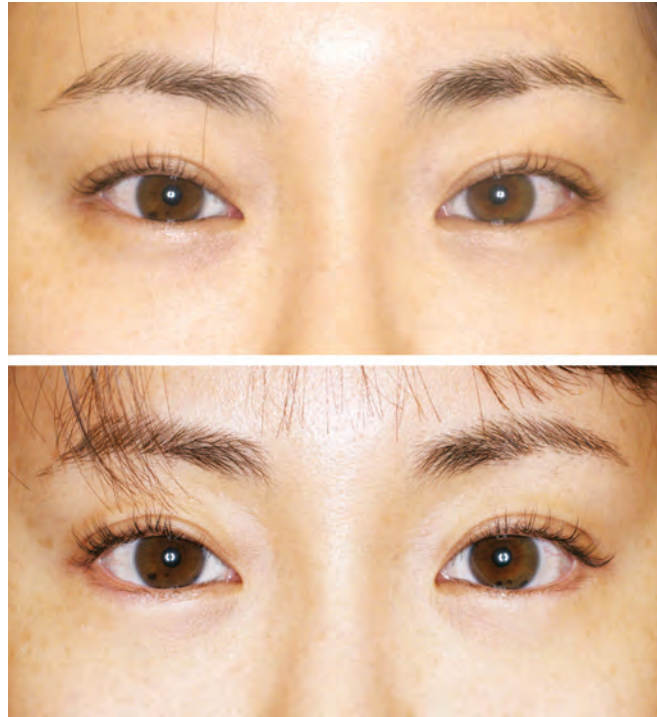
normal anatomical position has clinical implications for aesthetic appearance and to maintain sufficient corneal wetting. The descending lateral canthus is associated with the aging process<sup>24–26</sup>; because the lowering the lower eyelid procedure does not change the position of the lateral canthus, the postoperative eye became not an aged-appearing round eye but one that was oval and youthful appearing.

The horizontal laxity of the lower eyelid is noted less frequently in Asian than in Caucasian populations.<sup>27</sup> If eyelid laxity was identified preoperatively in the snapping back test, two surgical

options would be used in the lowering the lower eyelid procedure. One is transconjunctival shortening of the posterior lamella without the removal of the anterior lamella, which was occasionally performed in young patients. The other option is lateral canthopexy (lateral canthal repositioning), which may be required in patients with age-related lid laxity. These case-by-case modifications are important to minimize potential risks of the lowering the lower eyelid procedure, such as lower lid malposition.

Likewise, great care must be taken in the removal of the anterior lamella in patients with





**Fig. 8.** Patient 4 (lowering the lower eyelid procedure concomitant with transconjunctival partial levator shortening). A 34-year-old woman requested an enlargement of the palpebral aperture with a complaint about the up-slanting appearance of her eyes (*above*). Surprisingly, the inclination between the medial canthus and the lateral canthus measurements were less than the normal limit: 9.1 degrees (right) and 9.3 degrees (left). We planned to correct the medial portion of her upper lid with partial levator shortening through the transconjunctival approach and the lateral portion of her lower lid using the lowering the lower eyelid procedure. A total of 5 mm of lower lid skin was removed on both sides. She was satisfied with her enlarged palpebral apertures (at 14 months; *below*). Morphometric evaluation showed that the height of palpebral aperture at the midpupil increased from 8.0 mm to 10.0 mm on the right side and from 8.3 mm to 10.0 mm on the left side. The height of the palpebral aperture at the lateral limbus margin increased from 7.2 mm to 8.9 mm on the right side and from 8.2 mm to 9.4 mm on the left side. The area of palpebral aperture also increased from 1.39 cm<sup>2</sup> to 1.84 cm<sup>2</sup> on the right and from 1.53 cm<sup>2</sup> to 1.96 cm<sup>2</sup> on the left side.

globe proptosis and hypoplasia of the malar eminence. In these cases, transconjunctival posterior lamella shortening should be performed initially, and thereafter it should be determined whether resection of the anterior lamella is needed. In contrast, patients with deep-set eyes tend to present insufficient efficacy with the lowering the lower eyelid procedure so that a few more millimeters of skin may be removed compared with patients with normal eyes.

Hypertrophy of the orbicularis oculi muscle is a unique feature of the Asian population,<sup>28</sup> which is not always a complaint; it is considered attractive by some Asian women. In our series, the orbicularis muscle was left intact in all patients, and none of them requested a revision of this portion. Interestingly, the pretarsal bulging frequently became flattened after the lowering the lower eyelid procedure (Figs. 5 through 7), likely because of tightening of the lower lid skin. However, if re-

**Table 2. Morphometric Data from the Demonstrated Cases**

Patient	iML (degrees)	aPA (cm <sup>2</sup> )		hPAM (mm)		hPAL (mm)	
		Preoperatively	Postoperatively	Preoperatively	Postoperatively	Preoperatively	Postoperatively
1							
Right eye	11.6	1.52	1.83	8.5	9.9	6.0	7.7
Left eye	11.2	1.45	1.68	8.3	9.0	5.9	7.6
2							
Right eye	12.2	1.63	1.76	8.9	9.7	7.0	7.9
Left eye	13.6	1.57	1.79	9.0	10.1	7.4	8.3
3							
Right eye	12.4	1.37	1.67	8.2	9.3	6.4	8.0
Left eye	12.2	1.34	1.49	8.0	8.8	7.0	8.2
4							
Right eye	9.1	1.39	1.84	8.0	10.0	7.2	8.9
Left eye	9.3	1.53	1.96	8.3	10.0	8.2	9.4

iML, inclination between medial canthus and lateral canthus; aPA, area of palpebral aperture; hPAM, height of palpebral aperture at the midpupil; hPAL, height of palpebral aperture at the lateral limbus margin.

quested, the orbicularis muscle may be thinned by resection of a portion of its anterior surface without disturbing its tarsal attachment, thus preserving the lid tone as much as possible.

## CONCLUSIONS

The lowering the lower eyelid procedure was offered as a novel, effective option for patients desiring large oval eyes as an independent or ancillary procedure, although the indications are relatively limited. It has proven to be a reliable and consistent technique, and provided satisfactory results in a certain subset of patients. It remains possible that the lowering the lower eyelid procedure may be widely applicable to non-Asian patients who desire an enlarged palpebral aperture after careful preoperative evaluation, consultation, and informed consent.

**Toshitsugu Hirohi, M.D.**

Ritz Cosmetic Surgery Clinic Tokyo  
Meguro-Toho Building 8F  
3-1-7 Kamiosaki  
Shinagawa-ku, Tokyo 141-0021, Japan  
hirohi@ritz-cs.com

## REFERENCES

- Yaremchuk MJ. Restoring palpebral fissure shape after previous lower blepharoplasty. *Plast Reconstr Surg.* 2003;111:441–450.
- Zarem HA, Resnick JI. Expanded applications for transconjunctival lower lid blepharoplasty. *Plast Reconstr Surg.* 1991;88:215–220.
- Lisman RD, Hyde K, Smith B. Complications of blepharoplasty. *Semin Ophthalmol.* 1989;4:242–267.
- McCord CD Jr, Ellis DS. The correction of lower lid malposition following lower lid blepharoplasty. *Plast Reconstr Surg.* 1993;92:1068–1072.
- Jelks GW, Jelks EB. Repair of lower lid deformities. *Clin Plast Surg.* 1993;20:417–425.
- Tipton JB. Priority regarding transconjunctival blepharoplasty (Discussion). *Plast Reconstr Surg.* 1992;89:765.
- Ousterhout DK. Transconjunctival lower eyelid blepharoplasty (Discussion). *Plast Reconstr Surg.* 1992;89:1176.
- Mommaerts MY, De Riu G. Prevention of lid retraction after lower lid blepharoplasties: An overview. *J Craniomaxillofac Surg.* 2000;28:189–200.
- Lelli GJ Jr, Lisman RD. Blepharoplasty complications. *Plast Reconstr Surg.* 2010;125:1007–1017.
- Carraway JH, Mellow CG. The prevention and treatment of lower lid ectropion following blepharoplasty. *Plast Reconstr Surg.* 1990;85:971–981.
- Netscher DT, Patrinely JR, Peltier M, Polsen C, Thornby J. Transconjunctival versus transcutaneous lower eyelid blepharoplasty: A prospective study. *Plast Reconstr Surg.* 1995;96:1053–1060.
- Rees TD. Prevention of ectropion by horizontal shortening of the lower lid during blepharoplasty. *Ann Plast Surg.* 1983;11:17–23.
- Lisman RD, Rees TD, Baker D, Smith B. Experience with tarsal suspension as a factor in lower lid blepharoplasty. *Plast Reconstr Surg.* 1987;79:897–905.
- Wolfe SA, Kearney R. Blepharoplasty in the patient with exophthalmos. *Clin Plast Surg.* 1993;20:275–283.
- Jelks GW, Jelks EB. Preoperative evaluation of the blepharoplasty patient: Bypassing the pitfalls. *Clin Plast Surg.* 1993;20:213–223.
- Fagien S, Elson ML. Facial soft-tissue augmentation with allogeneic human tissue collagen matrix (Dermalogen and Dermaplast). *Clin Plast Surg.* 2001;28:63–81.
- McCord CD, Groessl SA. Lower-lid dynamics: Influence on blepharoplasty and management of lower-lid retraction. *Oper Tech Plast Reconstr Surg.* 1998;5:99–108.
- McCord CD Jr. The correction of lower lid malposition following lower lid blepharoplasty. *Plast Reconstr Surg.* 1999;103:1036–1039.
- Shorr N, Fallor MK. “Madame Butterfly” procedure: Combined cheek and lateral canthal suspension procedure for post-blepharoplasty “round eye” and lower eyelid retraction. *Ophthalm Plast Reconstr Surg.* 1985;1:229–235.
- Spinelli HM. Eyelid malpositions. In: Spinelli HM, ed. *Atlas of Aesthetic Eyelid & Periocular Surgery*. 1st ed. Philadelphia: Saunders; 2004:34–35.
- Jelks GW, Glat PM, Jelks EB, Longaker MT. The inferior retinacular lateral canthoplasty: A new technique. *Plast Reconstr Surg.* 1997;100:1262–1270.
- Glat PM, Jelks GW, Jelks EB, Wood M, Gadangi P, Longaker MT. Evolution of the lateral canthoplasty: Tech-

- niques and indications. *Plast Reconstr Surg.* 1997;100:1396–1405.
23. Park DH, Choi WS, Yoon SH, Song CH. Anthropometry of Asian eyelids by age. *Plast Reconstr Surg.* 2008;121:1405–1413.
  24. Shore JW. Changes in lower eyelid resting position, movement, and tone with age. *Am J Ophthalmol.* 1985;99:415–423.
  25. Neuhaus RW. Anatomical basis of “senile” ectropion. *Ophthalm Plast Reconstr Surg.* 1985;1:87–89.
  26. Ousterhout DK, Weil RB. The role of the lateral canthal tendon in lower eyelid laxity. *Plast Reconstr Surg.* 1982;69:620–623.
  27. Mustarde JC. *Repair and Reconstruction in the Orbital Regions.* Edinburgh: Livingstone; 1969.
  28. McCurdy JA. Lower blepharoplasty in the Asian. In: McCurdy JA, Lam SM, eds. *Cosmetic Surgery of the Asian Face.* 2nd ed. New York: Thieme; 2005:34–41.

## Online CME Collections

This partial list of titles in the developing archive of CME article collections is available online at [www.PRSJournal.com](http://www.PRSJournal.com). *These articles are suitable to use as study guides for board certification, to help readers refamiliarize themselves on a particular topic, or to serve as useful reference articles. Articles less than 3 years old can be taken for CME credit.*

### Cosmetic

- The Silicone Gel-Filled Breast Implant Controversy: An Update**—Arshad R. Muzaffar and Rod J. Rohrich
- Understanding the Nasal Airway: Principles and Practice**—Brian K. Howard and Rod J. Rohrich
- Lateral Canthal Anchoring**—Clinton McCord et al.
- Male Rhinoplasty**—Rod J. Rohrich et al.
- The Cosmetic Use of Botulinum Toxin (October 2003 Supplement)**—Rod J. Rohrich et al.
- Thrombolytic Therapy following Rhytidectomy and Blepharoplasty**—Stephanie L. Mick et al.
- Current Concepts in Aesthetic Upper Blepharoplasty**—Rod J. Rohrich et al.
- Breast Augmentation: Cancer Concerns and Mammography—A Literature Review**—Michael G. Jakubietz et al.
- Prevention of Venous Thromboembolism in the Plastic Surgery Patient**—Steven Paul Davison et al.
- Breast Augmentation**—Scott L. Spear et al.
- Otoplasty: Sequencing the Operation for Improved Results**—James Hoehn and Salman Ashruf
- Thromboembolism in Plastic Surgery**—Daniel Most et al.
- Otoplasty**—Jeffrey E. Janis et al.
- Fire in the Operating Room: Principles and Prevention**—Stephen P. Daane and Bryant A. Toth
- Patient Safety in the Office-Based Setting**—J. Bauer Horton et al.
- Frequently Used Grafts in Rhinoplasty: Nomenclature and Analysis**—Jack P. Gunter et al.
- Injectable Soft-Tissue Fillers: Clinical Overview**—Barry L. Eppley and Babak Dadvand
- Body Dysmorphic Disorder and Cosmetic Surgery**—Canice E. Crerand et al.
- Use of Herbal Supplements and Vitamins in Plastic Surgery: A Practical Review**—George Broughton, II, et al.
- Psychological Considerations of the Bariatric Patient**—David Sarwer