

A Clinical Trial of Topical Bleaching Treatment with Nanoscale Tretinoin Particles and Hydroquinone for Hyperpigmented Skin Lesions

KATSUJIRO SATO, MD,* DAISUKE MATSUMOTO, MD,* FUMIKO IZUKA, MD,* EMIKO AIBA-KOJIMA, MD,* CHIAKI MACHINO, MD,* HIROTAKA SUGA, MD,* ASAMI WATANABE-ONO, MD,† KEITA INOUE, MD,* KOICHI GONDA, MD,* AND KOTARO YOSHIMURA, MD*

BACKGROUND Although combined use of tretinoin (all-*trans*-retinoic acid; atRA) and hydroquinone improves various hyperpigmented lesions, the pharmacologic instability of atRA and atRA-induced irritant dermatitis are difficult unsolved problems.

OBJECTIVE The objective was to evaluate the efficacy and adverse effects of a newly formulated gel containing inorganic-coated atRA nanoscale particles (nano-atRA gel).

METHODS Nano-atRA gel was used in our two-phased bleaching protocol: 5% hydroquinone and 7% lactic acid ointment were used along with nano-atRA gel in the bleaching phase (2–8 weeks), and 5% hydroquinone and 7% ascorbic acid ointment were used alone during the healing phase (4–8 weeks). Eighty-four patients with facial hyperpigmented lesions were enrolled in this study, and 77 of them (88 lesions) followed up for more than 10 weeks were analyzed.

RESULTS Hyperpigmentation was improved in 84 of 88 lesions (95.5%) after a mean treatment period of 14.3 weeks and was almost eliminated in 52 lesions (59.1%). Nano-atRA gel caused exfoliation and scaling similar to that seen with conventional atRA gel, whereas the erythema seen in the bleaching phase appeared to be weaker.

CONCLUSION Nano-atRA gel can improve hyperpigmentation to a similar extent as conventional atRA gel. It also induces irritant dermatitis, but with less erythema.

The authors have indicated no significant interest with commercial supporters.

The combination of topical tretinoin (all-*trans*-retinoic acid; atRA) and hydroquinone is effective on various hyperpigmented skin disorders. Kligman and Willis¹ introduced this treatment, and several modified protocols² have been reported. In these therapeutic regimens, topical corticosteroids are used in combination with atRA and hydroquinone to reduce adverse effects such as irritation and erythema. We have previously proposed aggressive bleaching protocols,^{3–5} in which atRA and hydroquinone were used separately. Corticosteroids were not used, because corticosteroids reduce the melanin-discharging effect of atRA.^{6–9} Corticosteroids can lead to postinflammatory hyperpigmentation (PIH) in bleaching therapy, especially in colored

skin, probably by suppressing epidermal turnover and melanin discharge. Since 1995, we have successfully treated more than 15,000 cases of various skin lesions with epidermal hyperpigmentation using our bleaching protocols.

In our combined bleaching treatment with atRA and hydroquinone, atRA discharges melanin granules from the epidermis by accelerating epidermal turnover,^{8–10} whereas hydroquinone strongly suppresses new melanin production.¹¹ The hyperpigmented epidermis is replaced by less-pigmented epidermis in a few weeks. atRA promotes the discharge of melanin granules in epidermis by (1) accelerating epidermal turnover (differentiation of keratinocytes)

*Department of Plastic Surgery; University of Tokyo School of Medicine, Tokyo; †Ritz Medical Clinic, Tokyo, Japan

in a direct manner and (2) promoting epidermal growth (proliferation of keratinocytes) in an indirect manner; the latter effect was found to be mediated by heparin-binding epidermal growth factor–like growth factor (HB-EGF) secreted by suprabasal keratinocytes.^{10,12} Thus, atRA has a specific effect as a discharger of epidermal melanin that cannot be performed by any other reagents or any peeling procedures such as α -hydroxyl acid peeling or microdermabrasion. These exfoliating procedures simply induce subsequent normal wound healing and only minimal acceleration of epidermal turnover.

It is well known, however, that atRA frequently induces irritant dermatitis, especially when used aggressively. Because all-*trans*-retinol (ROL) and all-*trans*-retinal had been considered to be less irritating than atRA,^{13,14} we tried using 10% ROL aqueous gel instead of 0.1% atRA gel and achieved similar effectiveness, but failed to reduce the adverse effects.⁷ As yet, there is no way to reduce the irritant dermatitis without losing the bleaching efficacy of retinoids.

Nanoscale atRA (nano-atRA) particles were developed as a novel drug delivery system through the use of a boundary-organized nanoscale reaction.¹⁵ The poor stability of atRA to heat and light is a serious pharmacologic problem: our handmade, aqueous atRA gel requires monthly preparation.^{3–9} Nano-atRA showed improved stability compared with atRA¹⁵ and can be stocked for 6 months. In addition, nano-atRA particles showed improved permeation of the stratum corneum, and atRA should be gradually released in the epidermis as nanoscale micells degrade. In murine skin, nano-atRA gel contributed to accelerated epidermal turnover, epidermal hyperplasia, decreasing melanin content, increased expression of hyaluronic acid, and increased HB-EGF mRNA levels in epidermal keratinocytes.¹⁵ Enhanced production of HB-EGF by suprabasal keratinocytes is known to be one of the important phenomena seen after topical retinoid treatment¹² and is the most likely mechanism by which retinoids accelerate the discharge of epidermal melanins.¹⁰

Improved permeation and slow release of atRA from nanoscale particles may enhance its clinically beneficial effects and/or reduce its adverse effects, such as retinoid dermatitis. In this trial study, we prepared 0.1, 0.2, and 0.4% nano-atRA gels for clinical use to estimate the bleaching potential of nano-atRA gel and the extent of its adverse side effects.

Methods

Preparation of Ointments

atRA was commercially obtained from Wako Pure Chemical Industries Ltd. (Osaka, Japan), and 0.1, 0.2, and 0.4% nano-atRA gels were prepared using boundary-organized nanoscale reaction droplets as previously reported¹⁵ (Figure 1). The size and structure of the nano-atRA particles were confirmed by freeze fracture transmittance electron microscopy (ff-TEM, Hitachi Co. Ltd, Tokyo, Japan). The nano-atRA gels were prepared at Institute of Medical Science, St. Marianna University School of Medicine. An ointment including 5% hydroquinone and 7% lactic acid (HQ-LA ointment) and an ointment including 5% hydroquinone and 7% ascorbic acid (HQ-AA ointment) were also prepared. Petrolatum polyethylene ointment base (Plastibase, Taisho Pharmacology, Osaka, Japan) was used as the ointment base of the HQ-LA ointment, whereas a hydrophilic ointment (Taisho Pharmacology) was used for the HQ-AA ointment.

Patients

Each ointment was applied topically by 83 Japanese women and 1 man with facial hyperpigmented skin lesions, and the 77 patients (76 women and 1 man) who were followed up for more than 10 weeks were analyzed in this study. Because 11 patients had two lesions, there were 88 hyperpigmented skin lesions in all, including solar lentigines ($n = 10$), melasma ($n = 36$), ephelides ($n = 9$), and PIH ($n = 33$). Dermal melanosis and melanocytosis were not targeted. The other 7 patients stopped the treatment because of their private reasons or adverse side effects such as

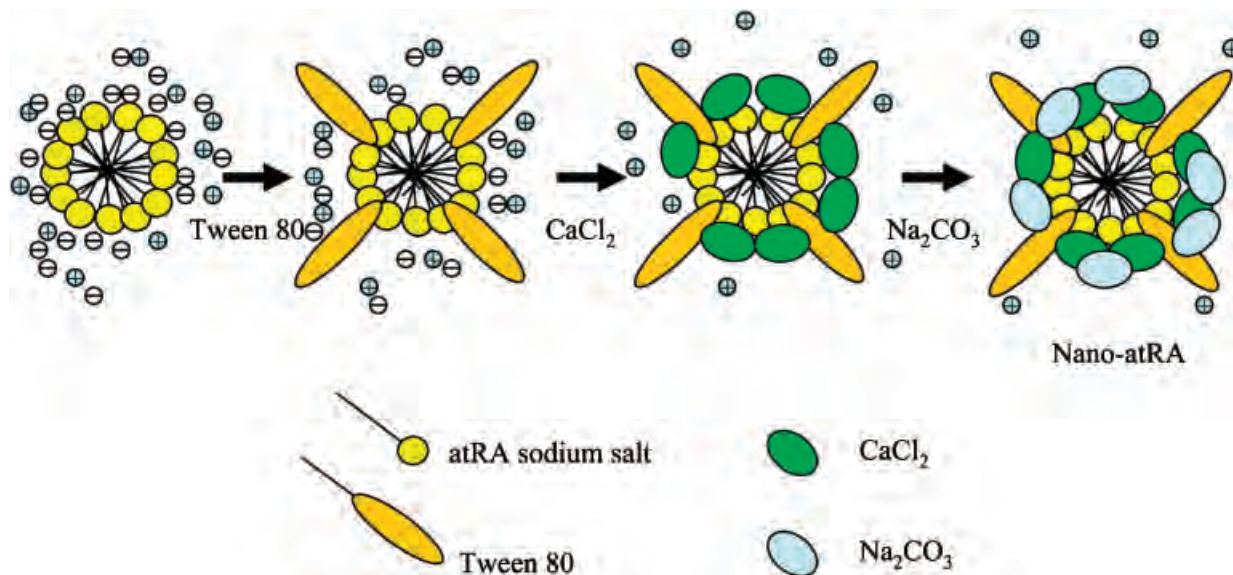


Figure 1. Schematic of the preparation of nano-atRA particles with their core/shell (CaCO_3) structure.

irritation and erythema. The age of the patients ranged from 16 to 84 years (mean \pm SD, 45.2 ± 15.4 years).

Informed consent was obtained from all subjects. The study protocol conformed to the guidelines of the 1975 Declaration of Helsinki and was approved by our institutional review board.

Treatment Protocol

Our bleaching protocol consists of two phases, a bleaching phase and a healing phase.⁶⁻⁹ In the bleaching phase, discharge of epidermal melanin is accelerated by nano-atRA gel and melanin production is suppressed by HQ-LA ointment. In the healing phase, the discharge of epidermal melanin is discontinued and great care is taken not to induce new PIH, by using hydroquinone alone.

In the bleaching phase, 0.1% nano-atRA gel and HQ-LA ointment were applied twice a day. All patients were started with 0.1% atRA, and higher percentages (0.2 or 0.4%) of tretinoin were used only when patients did not see skin reactions such as scaling. Nano-atRA gel was carefully applied only to

pigmented areas, using a small cotton-tip applicator, and subsequently HQ-LA ointment was widely applied with the fingers beyond the pigmented area (i.e., all over the face). Patients were asked to visit our hospital at 1, 2, 4, 8, and 12 weeks after starting this treatment. In most cases, it took 2 to 8 weeks to finish this phase. When scaling was not observed at 1 week, the concentration of tretinoin was increased to 0.2 or 0.4%. The concentration of tretinoin and frequency of its application were appropriately modified according to the skin condition and the degree of skin reaction.

The healing phase was begun after pigmentation had improved sufficiently or 8 weeks had passed. The application of nano-atRA gel and HQ-LA ointment was discontinued, and application of HQ-AA ointment all over the face was started. HQ-AA ointment was used until the erythema was almost eliminated; it took 4 to 8 weeks to complete this phase. Topical corticosteroids were not employed in the bleaching or healing phase. In melasma patients, a second treatment, which is a complete treatment cycle including bleaching and healing phases, was performed after a 1-month interval if the patient requested it.

TABLE 1. Clinical Results of Nano-atRA Treatment

Skin pigmentation disorder	Mean treatment period (weeks)	Number of lesions					Total
		Excellent	Good	Fair	Poor		
Solar lentigines	13.6	1 (10.0%)	3 (30.0%)	4 (40.0%)	2 (20.0%)	10 (100%)	
Melasma	14.1	17 (47.2%)	11 (30.5%)	6 (16.7%)	2 (5.6%)	36 (100%)	
Ephelides	16.5	2 (22.2%)	3 (33.3%)	4 (44.4%)	0 (0%)	9 (100%)	
PIH	14.2	27 (81.8%)	5 (15.2%)	1 (3.3%)	0 (0%)	33 (100%)	
Total	14.3	47 (53.4%)	22 (25.0%)	15 (17.0%)	4 (4.5%)	88 (100%)	

PIH, postinflammatory hyperpigmentation.

Evaluation of Results

Photographs of each patient were taken at baseline and during and after treatment with a high-resolution digital camera (D70, Nikon, Tokyo, Japan). The percentage of pigmentary clearance was evaluated via the photographs by two experienced plastic surgeons who did not perform this treatment. The mean data of the pigmentary clearance of each patient were classified into four categories: excellent (80% clearance or better), good (50% to less than 80% clearance), fair (0% to less than 50% clearance), and poor (no change or worse).

Results

The 88 hyperpigmented lesions were treated for a mean period of 14.3 weeks. Almost all patients had sufficient improvement without serious adverse effects. Mild erythema appeared in the first week in most cases and scaling was seen at the same time. Clinical evaluations of patients at 1 and 2 weeks suggested that nano-atRA gel appeared to induce a lesser degree of erythema and a similar degree of scaling in the first 2 weeks compared to our thousands of cases treated with conventional atRA gel,³⁻⁹ although statistical analysis of erythema was not performed. Scaling is a clinical sign of accelerating epidermal turnover in this treatment, and if scaling was not seen during the first or second week of treatment, we changed the concentration of atRA from 0.1% to 0.2 or 0.4%. Scaling was observed even in the initial stage of the healing phase, suggesting that the slow-release nano-atRA gel had

long-term effects. Continuous use of atRA always induced less response of skin (such as scaling) in our conventional atRA treatment, and thus we frequently had to change the concentration of atRA by the fourth week. The resistance to atRA was also seen with the nano-atRA treatment.

The results of this study are summarized in Tables 1 and 2. Forty-seven lesions (53.5%) were evaluated as “excellent,” 22 (25.0%) as “good,” 15 (17.0%) as “fair,” and 4 (4.5%) as “poor.” Most of the fair and poor cases had minimal skin reactions, such as scaling, during the bleaching phase. Representative cases are shown in Figures 2 through 4.

Nano-atRA improved all four kinds of skin pigmentation disorders. Of 36 cases of melasma, 28 (79.3%) ranked excellent or good. The mean treatment period of melasma patients was 14.1 weeks. Thirty-two of 33 PIH cases ranked excellent or good. There were no poor results in the PIH group. There were only 9 cases of ephelides, more than half of which achieved excellent or good results.

TABLE 2. Clinical Results of Cases with Melasma

Number of treatments	Number of cases					Excellent Total cases (%)
	Excellent	Good	Fair	Poor		
One treatment	12	10	5	1	28	42.8
Two treatments	5	1	1	1	8	62.5
Total	17	11	6	2	36	47.2

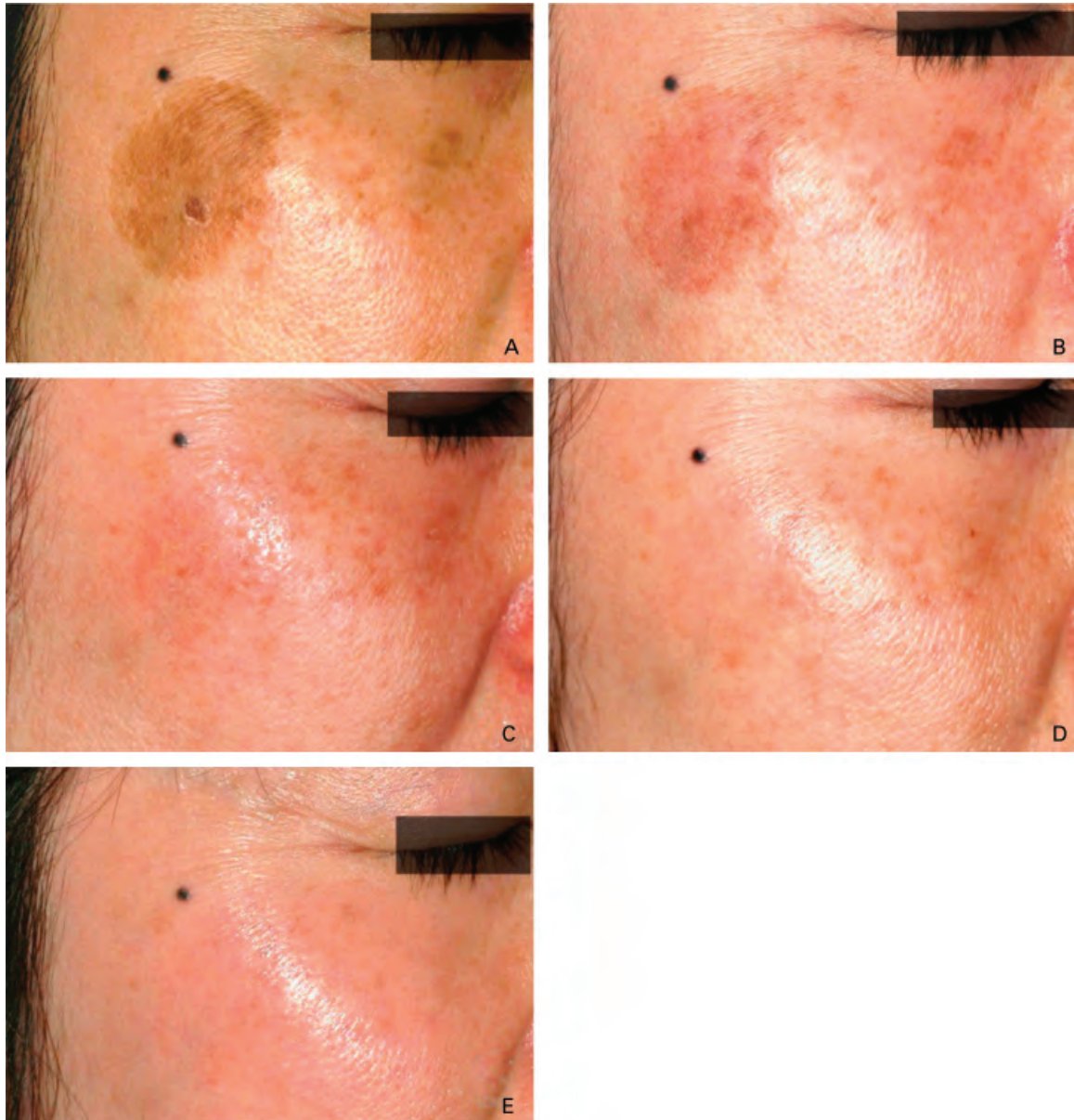


Figure 2. Case 1: A 40-year-old woman with a solar lentigine and melasma on her right cheek, first shown before treatment (A). The solar lentigine was first treated with a Q-switched ruby laser, but 4 weeks later PIH appeared at the original position (B). Bleaching treatment with 0.1% nano-atRA gel and HQ-LA ointment was performed for 4 weeks; the patient is shown at 2 weeks (C) and at 4 weeks (D). This was followed by healing treatment with HQ-AA ointment alone for 4 weeks. Only minimal erythema appeared during the bleaching phase. PIH was completely eliminated and the melasma was also apparently improved at 8 weeks (E).

Only 4 of 88 lesions (2 of melasma and 2 senile lentigines) showed poor treatment results.

Discussion

In our recent report, we used histology to confirm that accumulated melanin granules around the basal

layer were cleared after treatment with atRA and hydroquinone. In acquired dermal melanocytosis, melanin deposits in the dermis appeared not to change.⁸ Thus, the bleaching therapy is only effective for epidermal pigmentation, and we therefore focused on various types of hyperpigmentation of the epidermis in this trial.

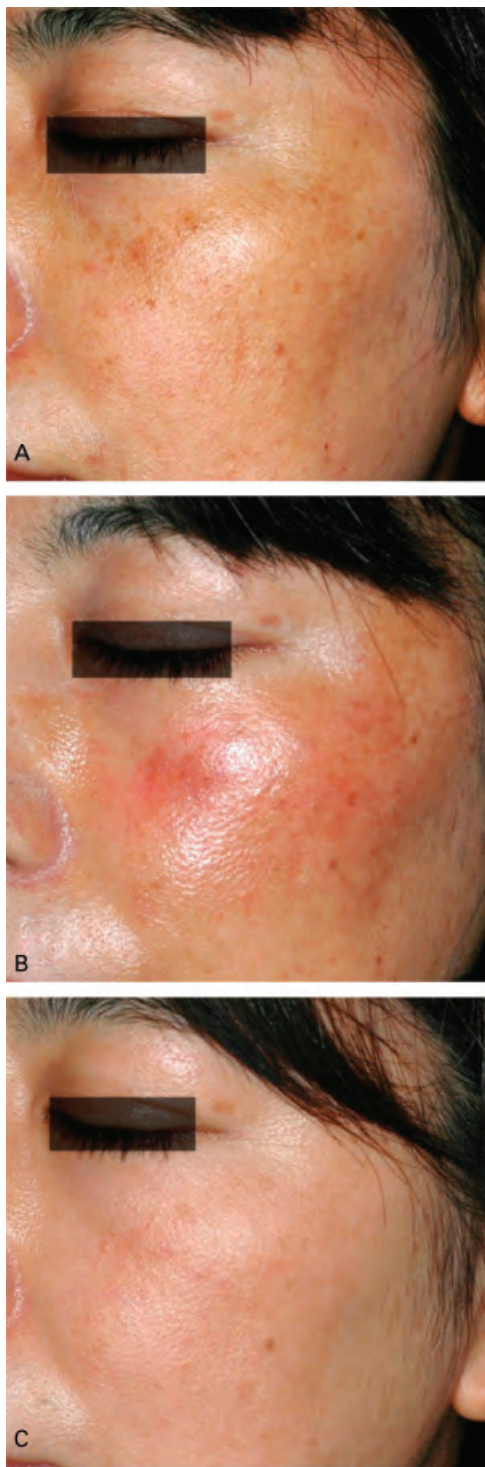


Figure 3. Case 2: A 38-year-old woman with melasma on both cheeks is shown before the treatment (A). Bleaching with 0.1% nano-atRA gel and HQ-LA ointment was performed for 12 weeks, followed by application of HQ-AA ointment alone for 4 weeks. Mild erythema appeared during the bleaching phase, shown at 4 weeks (B). The melasma was almost cleared at 16 weeks (C).

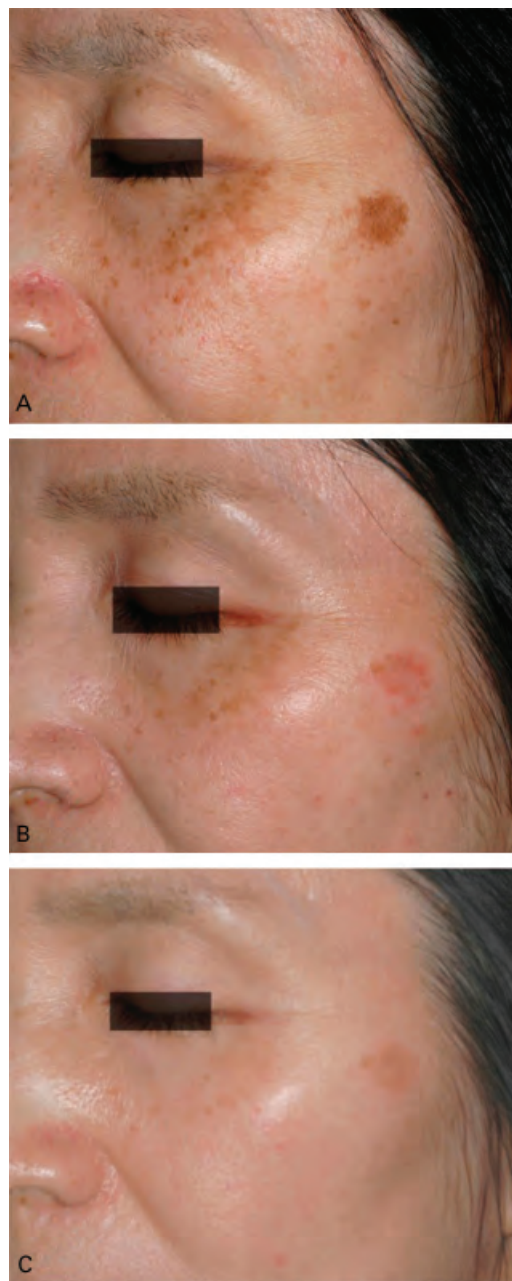


Figure 4. Case 3: A 53-year-old woman with a solar lentigine and melasma on her left cheek before the treatment (A). 0.1% nano-atRA gel was used together with HQ-LA ointment in bleaching phase for 12 weeks, and HQ-AA ointment was applied alone in the healing phase for 9 weeks. Mild erythema was seen during the bleaching phase, shown at 4 weeks (B). The melasma almost disappeared, whereas the solar lentigine became lighter, as seen at 21 weeks (C).

Using nano-atRA gel based on the newly developed drug delivery system technology, we obtained results as good as those of previous studies that used our

former atRA gel. The present treatment resulted in satisfactory improvement of melasma, with a mean treatment period of 14.1 weeks. Roughly two-thirds of the melasma patients required only one session of the bleaching treatment (Table 2), whereas treatment of melasma with our former atRA gel was sometimes performed in two or three sessions.⁸ Of the various hyperpigmented lesions treated, PIH was most improved. This has always been true in our treatment of lesions with conventional atRA. The number of patients with ephelides enrolled in this study was small, but more than half of the patients showed excellent or good results. Among the four types of hyperpigmented lesions studied, the percentage of excellent and good results was lowest in the senile lentigines. Senile lentigines, especially those that are resident for a long period, frequently show excessive development of horny layers (hyperkeratosis) that may obstruct the penetration of atRA into the epidermis. This may also be the case with nano-atRA gel, although high permeation of nano-atRA was reported in murine skin.¹⁵ We recommend that irradiation by Q-switched ruby laser for removal of hyperkeratinization of senile lentigines (CO₂ laser for debulking extreme hyperkeratinization of seborrheic keratoses) is first performed as done in Case 1 (Figure 2). In colored skin, PIH after laser treatments can frequently be a disfiguring problem. PIH after laser irradiation, however, is always easily treated by our aggressive bleaching treatment with atRA and hydroquinone^{3,4,8,9} especially when the laser irradiation is only once and the bleaching treatment started early (e.g., 4 weeks after Q-switched laser irradiation).

In our conventional bleaching treatment, there are two major problems: one is dermatitis induced by aggressive use of atRA, and the other is the biochemical instability of atRA in our ointments. We applied atRA only on the pigmented area but used it aggressively, which almost always led to irritant dermatitis on the area where it was applied. The dermatitis is the most serious side effect and remains to be resolved. In animal experiments, nano-atRA gel showed slower diffusion into the epidermis and

higher degrees of epidermal alterations, as assessed by retinoid signals such as elevated HB-EGF mRNA expression, enhanced hyaluronic acid deposition, and epidermal hyperplasia, with a lesser degree of erythema.¹⁵ These advantages of nano-atRA appeared to be partly confirmed in this clinical trial, in which similar degrees of bleaching effectiveness and scaling were seen, with a lesser degree of erythema. In addition, the improved biochemical stability of nano-atRA to heat and light is another advantage,¹⁵ because we had to prepare the conventional atRA gel every month because of its pharmacological instability. The fact that nano-atRA gel can be stored for at least 6 months without significantly losing atRA chemical activity may increase its commercial profitability. atRA has long been used for treating acne, photoaging-associated symptoms such as fine wrinkles, and hyperpigmentation. When used aggressively, atRA can be an extremely powerful tool for discharging epidermal melanin. Reducing retinoid-induced dermatitis remains a major challenge. New generations of synthetic retinoids or new drug delivery systems, such as the nano-atRA presented here, may resolve the problem.

Acknowledgments Nano-atRA gels used in this study were gifts from Dr Yoko Yamaguchi and Dr Rie Igarashi of Institute of Medical Science, St. Marianna University School of Medicine.

References

1. Kligman AM, Willis I. A new formula for depigmenting human skin. *Arch Dermatol* 1975;111:40-8.
2. Gano SE, Garcia RL. Topical tretinoin, hydroquinone, and beta-methasone valerate in the therapy of melasma. *Cutis* 1979;23:239-41.
3. Yoshimura K, Harii K, Aoyama T, et al. A new bleaching protocol for hyperpigmented skin lesions with a high concentration of all-trans retinoic acid aqueous gel. *Aesthetic Plast Surg* 1999; 23:285-91.
4. Yoshimura K, Harii K, Aoyama T, Iga T. Experience with a strong bleaching treatment for skin hyperpigmentation in Orientals. *Plast Reconstr Surg* 2000;105:1097-108.
5. Yoshimura K, Harii K, Masuda Y, et al. Usefulness of a narrow-band reflectance spectrophotometer in evaluating effects of depigmenting treatment. *Aesthetic Plast Surg* 2001;25:129-33.

6. Yoshimura K, Momosawa A, Watanabe A, et al. Cosmetic color improvement of the nipple-areola complex by optimal use of tretinoin and hydroquinone. *Dermatol Surg* 2002;28:1153-8.
7. Yoshimura K, Momosawa A, Aiba E, et al. Clinical trial of bleaching treatment with 10% all-trans retinol gel. *Dermatol Surg* 2003;29:155-60.
8. Momosawa A, Yoshimura K, Uchida G, et al. Combined therapy using Q-switched ruby laser and bleaching treatment with tretinoin and hydroquinone for acquired dermal melanocytosis. *Dermatol Surg* 2003;29:1001-7.
9. Yoshimura K, Sato K, Aiba-Kojima E, et al. Repeated treatment protocols for melasma and acquired dermal melanocytosis. *Dermatol Surg* 2006;32:365-71.
10. Yoshimura K, Uchida G, Okazaki M, et al. Differential expression of heparin-binding EGF-like growth factor (HB-EGF) mRNA in normal human keratinocytes induced by a variety of natural and synthetic retinoids. *Exp Dermatol* 2003;12(Suppl 2):28-34.
11. Yoshimura K, Tsukamoto K, Okazaki M, et al. Effects of all-trans retinoic acid on melanogenesis in pigmented skin equivalents and monolayer culture of melanocytes. *J Dermatol Sci* 2001;27(Suppl 1):S68-75.
12. Xiao JH, Feng X, Di W, et al. Identification of heparin-binding EGF-like growth factor as a target in intercellular regulation of epidermal basal cell growth by suprabasal retinoic acid receptors. *EMBO J* 1999;18:1539-48.
13. Kang S, Duell EA, Fisher GJ, et al. Application of retinol to human skin in vivo induces epidermal hyperplasia and cellular retinoid binding proteins characteristic of retinoic acid but without measurable retinoic acid levels or irritation. 1995; 105:549-56.
14. Fluhr JW, Vienne MP, Lauze C, et al. Tolerance profile of retinol, retinaldehyde and retinoic acid under maximized and long-term clinical conditions. *Dermatology* 1999;199(Suppl 1): 57-60.
15. Yamaguchi Y, Nagasawa T, Nakamura N, et al. Successful treatment of photo-damaged skin of nano-scale atRA particles using a novel transdermal delivery. *J Control Release* 2005; 104:29-40.

Address correspondence and reprint requests to:
 Kotaro Yoshimura, MD, Department of Plastic Surgery,
 University of Tokyo School of Medicine, 7-3-1 Hongo;
 Bunkyo-ku, Tokyo 113-8655, Japan, or
 e-mail: yoshimura-pla@h.u-tokyo.ac.jp